

Short Communication

Subconjunctival Infection with *Dirofilaria repens*

Vikas Gautam*, I. M. Rustagi¹, Satyavir Singh² and D. R. Arora

Department of Microbiology and

¹*Department of Ophthalmology, Postgraduate Institute of Medical Sciences, Rohtak and*

²*Department of Parasitology,*

Choudhary Charan Singh Hisar Agricultural University, Hisar, India

(Received February 14, 2002. Accepted March 18, 2002)

SUMMARY: Cases of zoonotic dirofilariasis infection, caused by *Dirofilaria repens*, occur widely throughout European, African, Middle Eastern, and Asian countries. The reports of this infection in humans in India are limited, and we herein report the case of a 23-year-old man who presented with subconjunctival swelling in the right eye with no local symptoms. A large nematode was visualized on examination and the intact worm was surgically removed. The parasite was identified as a male *D. repens*.

A 23-year-old man presented with a 20-day-old history of swelling in the right eye. His medical history showed no other complaints or any serious general health problems. The patient was a farmer by occupation and reported close association with domestic animals. He had no history of travelling abroad.

On ocular examination, his visual acuity was BE, 20/20. Slit-lamp examination disclosed a white, moving nematode that was coiled and located under the bulbar conjunctiva of the right eye, about 1.2 cm from the limbus and in the inferotemporal quadrant at the 4 o'clock meridian. A uniform, avascular swelling of 5 × 5 mm in the lateral canthal bulbar conjunctiva of right eye was present. The conjunctiva over the worm was only slightly elevated and not injected. The remainder of the anterior and posterior segment examination was unremarkable. The left eye was normal.

Under local anesthesia, the conjunctiva was incised over the site where the nematode was located. The live intact nematode performing peristaltic movements was grasped and removed (Figs. 1A, B), and preserved in 10% formaldehyde for identification. The conjunctiva was closed with 8-0 absorbable sutures.

The nematode was thin, cylindrical, and white with coiled ends. The worm was stretched and measured 8.3 cm long and 0.5 mm thick (Fig. 1C). The anterior end was bluntly rounded having a small mouth without buccal capsule (Fig. 1D). The cuticle of the worm, extending from the anterior end to the tail, had marked longitudinal ridges with transverse striations (Fig. 1E). The posterior end was slightly curved having papillae and unequal spicules with distinct caudal alae (Fig. 1F). The above features indicated that it was a male *Dirofilaria repens*. As expected, the patient's blood test results did not show microfilariae because this type of filaria usually remains subcutaneous or submucosal at the point of the bite of an insect vector. Routine laboratory tests were within normal limits.

Human dirofilariasis due to *Dirofilaria (Nochtiella) repens* (Nematoda, Onchocercidae) is a zoonosis habitually parasitizing carnivores, primarily dogs, foxes and cats, transmitted by the bite of mosquitoes, especially *Anopheles*, *Aedes*, and

Culex spp.(1). Review of world literature shows that 397 cases of human subcutaneous dirofilariasis caused by *D. repens* were recorded from 30 countries with endemic foci in Southern and Eastern Europe, Asia Minor, Central Asia, and Sri Lanka (2). However, the reports of this ocular infection in India are limited with the first report in the year 2000 by Sekhar et al. (3,4). To our knowledge this is the third such case report from India. Cases of subcutaneous dirofilariasis were originally called *Dirofilaria conjunctivae* because many of them localized in and around the eye and eyelids (5). *D. repens* is also believed to be synonymous with *D. tenuis*, which is endemic to the United States and is carried by raccoons. In humans, *D. repens* is the cause of local subcutaneous dirofilariasis and must be differentiated from *D. immitis*, which causes microfilaremia and requires the use of anthelmintic agents. *D. repens* displays longitudinal ridges, where *D. immitis* has a smooth cuticle, allowing the diagnosis of the species on a morphological basis (6).

Dirofilariasis should be considered in the differential diagnosis of lesions initially interpreted as malignant or benign tumors. Human cases of dirofilariasis are most probably underreported because many of them remain undiagnosed or unpublished (3,7). The surgical removal of the lesion not only establishes the diagnosis in most cases but also presents a definite cure.

ACKNOWLEDGMENTS

Thanks are due to Dr. R. Sehgal (Additional Professor), Dr. H.S. Bhatti (Lecturer), and Dr. Kavya Mohandas (Senior Resident) of Department of Parasitology, Postgraduate Institute of Medical Education and Research, Chandigarh, India, for rendering their help.

REFERENCES

1. Pampiglione, S., Rivasi, F., Angeli, G., Boldorini, R., Incensati, R. M., Pastormerlo, M., Pavese, M. and Ramponi, A. (2001): Dirofilariasis due to *Dirofilaria repens* in Italy, an emergent zoonosis: report of 60 new cases. *Histopathology*, 38, 344-354.
2. Pampiglione, S., Canestri Trotti, G. and Rivasi, F. (1995): Human dirofilariasis due to *Dirofilaria (Nochtiella) repens*: a review of world literature. *Parasitologia*, 37,

*Corresponding author: Mailing address: S/O Dr. S. P. Gautam, 3243 / 21-D, Chandigarh, India-160022. Tel: +91-172-707550, E-mail: r_vg@yahoo.co.uk

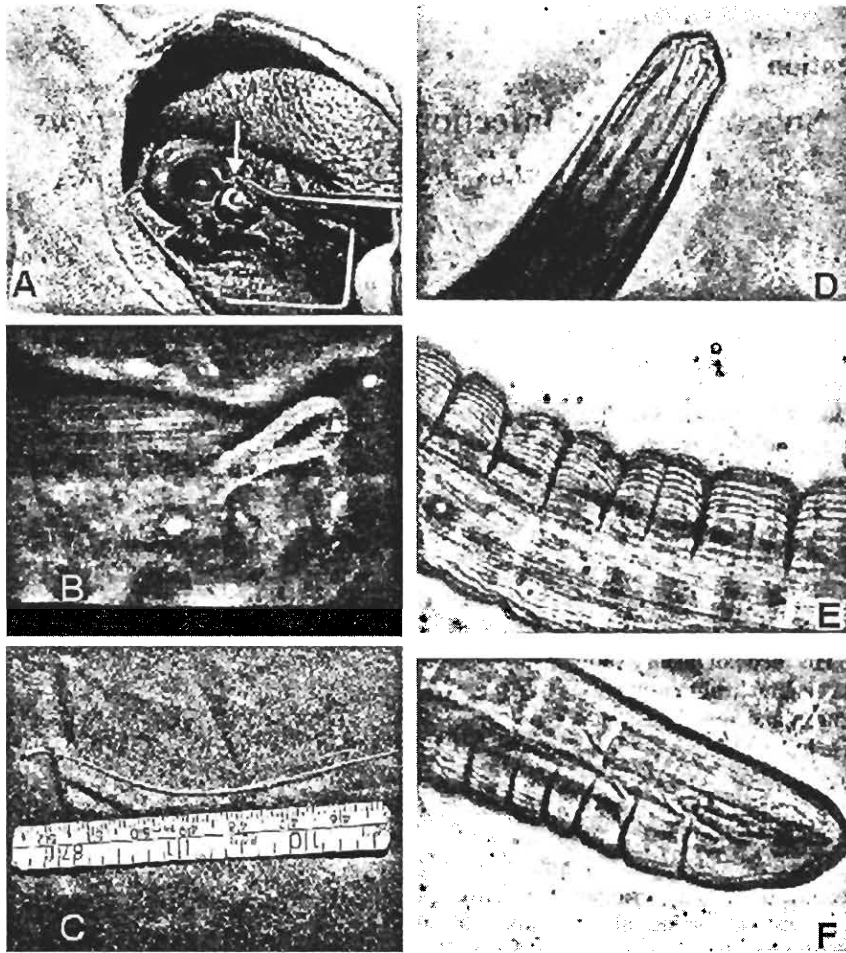


Fig. 1A: *Dirofilaria repens* adult worm rolling out of subconjunctiva (shown with arrow). B: *D. repens* grasped and removed from the subconjunctiva. C: Photograph of *D. repens* as removed from the subconjunctiva. D: Photomicrograph of anterior end of worm illustrated in part C (magnification, $\times 100$). E: Photomicrograph of surface of the worm's cuticle in part C, illustrating the nature of the ridges at the midbody level (magnification, $\times 100$). F: Photomicrograph of posterior end of worm illustrated in part C (magnification, $\times 100$).

- 149-193.
3. Sekhar, H. S., Srinivasa, H., Battu, R. R., Mathai, E., Shariff, S. and Macaden, R. S. (2000): Human ocular dirofilariasis in Kerala, Southern India. *Indian J. Pathol. Microbiol.*, 43, 77-79.
 4. Nadgir, S., Tallur, S. S., Mangoli, V., Halesh, L. H. and Krishna, B. V. (2001): Subconjunctival dirofilariasis in India. *Southeast Asian J. Trop. Med. Public Health*, 32, 244-246.
 5. Ruiz-Moreno, J. M., Bornay-Llinares, F. J., Prieto Maza, G., Medrano, M., Simon, F. and Eberhard, M. L. (1998): Subconjunctival infection with *Dirofilaria repens*: serological confirmation of cure following surgery. *Arch. Ophthalmol.*, 116, 1370-1372.
 6. Arvanitis, P. G., Vakalis, N. C., Damanakis, A. G. and Theodossiadis, G. P. (1997): Ophthalmic dirofilariasis. *Am. J. Ophthalmol.*, 123, 689-691.
 7. Logar, J., Novsak, V., Rakovec, S. and Stanisa, O. (2001): Subcutaneous infection caused by *Dirofilaria repens* imported to Slovenia. *J. Infect.*, 42, 72-74.