

Laboratory and Epidemiology Communications

Successful Treatment of Acute Myeloradiculoneuritis with High-Dose Corticosteroids in a Patient with Primary HIV-1 Infection

Chie Yasuoka, Yoshimi Kikuchi, Akira Yasuoka, Masazumi Yamaguchi, Yoshihiko Yamamoto, Ikumi Genka, Katsuji Teruya, Natsuo Tachikawa, Tomoyuki Shimpo<sup>1</sup> and Shinichi Oka\*

AIDS Clinical Center and <sup>1</sup>Department of Neurology, International Medical Center of Japan, Toyama 1-21-1, Shinjuku-ku, Tokyo 162-8655

Communicated by Hiroshi Yoshikura

(Accepted August 15, 2000)

Various neurological complications concomitant with HIV-1 seroconversion usually occur within 1 month of a mononucleosis-like illness. They include peripheral neuropathy, radiculopathy, facial palsy, Guillain-Barré syndrome, brachial neuritis, meningoencephalitis (1), ataxic neuropathy (2), and intracranial hypertension (3). However, myelopathy rarely appears, and only one case was reported in 1986 (4). We report here the first case of acute myeloradiculoneuritis (AMRN) treated successfully with high-dose corticosteroids in a patient with primary HIV-1 infection.

A 36-year-old man presented with a 2-week history of fever, fatigue, sore throat, and lymphadenopathy in early April of 1999. He visited a hospital on April 16. Aspartate

aminotransferase (AST) was 425 IU/l (normal < 35), alanine aminotransferase (ALT) was 380 IU/l (normal < 30), and alkaline phosphatase (ALP) was 1131 IU/l (normal < 340). IgM antibodies to cytomegalovirus (CMV) and Epstein-Barr virus, and IgG antibodies to hepatitis C virus were all negative. Hepatitis B surface antibody had previously been positive. An ultrasonic echogram (UEG) showed mild hepatomegaly, intra-abdominal lymphadenopathy, and a small cyst (1 cm in diameter) in a caudate lobe of the liver. The ELISA screening test for HIV-1 was positive. Western blot analysis revealed p55 and p24 bands. On April 26 he developed an unsteady gait and fell over while walking. He was referred to our hospital on April 28 (Figure) for treatment. Dysesthesia and

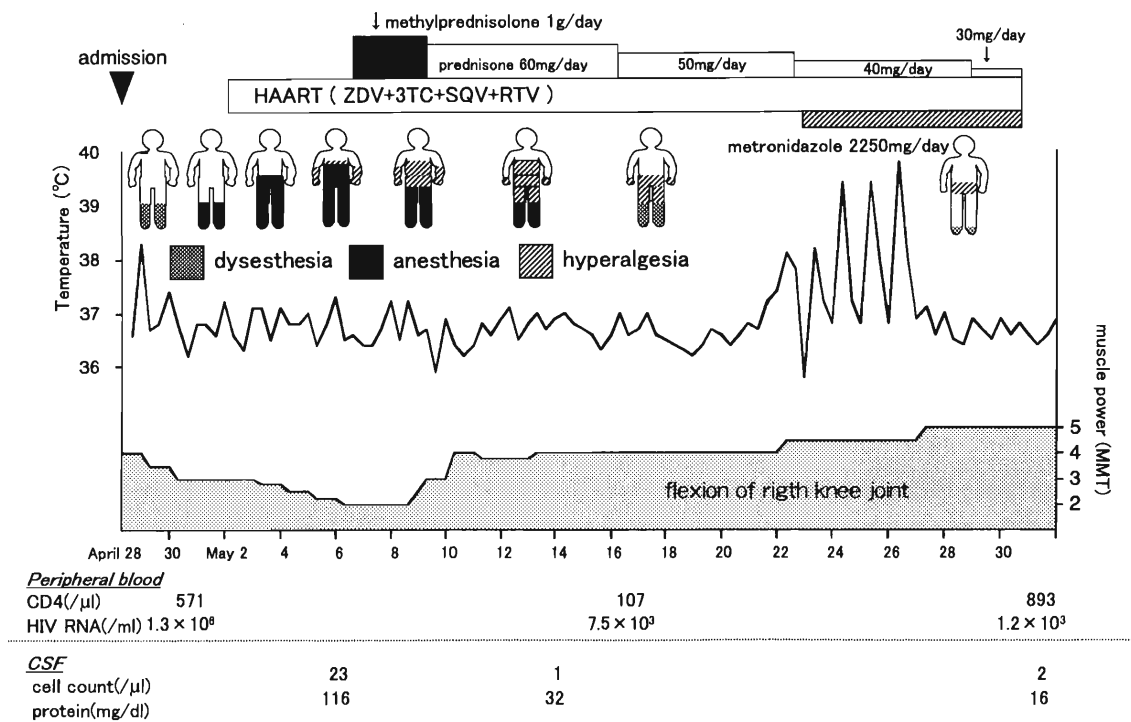


Figure. Clinical course of acute myeloradiculoneuritis in a patient with primary HIV-1 infection. HAART: highly active antiretroviral therapy; ZDV: zidovudine; 3TC: lamivudine; SQV: saquinavir; RTV: ritonavir; CSF: cerebrospinal fluid

\*Corresponding author: Tel/Fax: +81-3-5273-5193, E-mail: oka@imcj.hosp.go.jp

paralysis under both knees were noted. Dysesthesia progressed to the nipple level, and anesthesia developed in the legs. Vesicorectal disorder soon appeared, and he was subsequently unable to walk even with support. A neurological examination on May 6 revealed loss of tactile and pain sensations below the Th3 level and a moderate loss of positional and vibratory sensations in the right leg. Mild dysesthesia also appeared in his forearms and hands. Flaccid paraplegia, areflexia and severe weakness (grade 2/5) of the muscles in the lower legs also appeared. Babinski sign was positive on both sides.

On admission, his leukocyte count was 14,300/ $\mu$ l (70% lymphocyte, 3% atypical lymphocyte). The CD4 count was 571/ $\mu$ l. The CD8 count was as high as 8,068/ $\mu$ l. AST was 229 IU/l, ALT was 341 IU/l, and ALP was 898 IU/l. In Western blot (LAV blot, FUJIREBIO INC., Tokyo) p18, p24, p55 and gp160 bands were detected. The plasma contained  $1.3 \times 10^6$  HIV-1 RNA copies/ml. CMV antigen was absent in the blood. On May 6, the cerebrospinal fluid (CSF) was clear; the total cell count (100% lymphocyte) was 23/ $\mu$ l, total protein was 116 mg/dl (IgG index 1.4; normal level < 0.7), and glucose was 45 mg/dl (normal range: 40 - 70). HIV-1 RNA in CSF was 36,000 copies/ml. Herpes simplex virus and varicella-zoster virus were negative in PCR assay. Brain CT and magnetic resonance imaging of the thoracic spinal cord identified no abnormal lesions. Evoked electromyogram (obtained on May 7) showed a normal amplitude of the M wave and a diminished F wave following stimulation of the right tibial nerve in the ankle. Motor conduction velocities in the right peroneal and tibial nerves were delayed to 36 m/s (normal range: 43 - 62) and 39 m/s (normal range: 41 - 62), respectively. That of the right median nerve (54 m/s) was within the normal range. Therefore, the lesions in the spinal cord, nerve roots or peripheral nerves were considered responsible for the neurological symptoms. Consequently, we diagnosed this neurological disorder as AMRN.

Highly active antiretroviral therapy (HAART) consisting of zidovudine, lamivudine, zalcitabine and saquinavir was commenced on May 3. However, the patient's neurological symptoms continued to deteriorate, and he developed dyspnea due to weakness of the abdominal muscles. Therefore, he was treated for 3 days (May 8 - 10) with 1 g/day of intravenous methylprednisolone and then with oral prednisone at an initial dose of 60 mg/day which was then tapered. This therapy dramatically improved the muscle weakness in the lower extremities and abdomen. Neurological symptoms did not worsen. Rather, all the symptoms disappeared in 6 weeks except for mild dysesthesia in the tip of the foot.

On May 19, 11 days after the start of the methylprednisolone treatment, the patient became febrile (39 - 40°C) and complained of epigastralgia. Abdominal computed tomography (CT) and

UEG showed multiple cysts in the liver. *Entamoeba histolytica* was detected in the aspirate of a cyst. He was then treated with metronidazole for 3 weeks. In June, HIV RNA was suppressed to under 400/ml, but in Western blot all the HIV bands were detectable. The *Entamoeba histolytica* liver abscess was successfully treated. The patient was able to resume his former way of life 6 weeks after admission to our hospital.

The patient received HAART at the time of seroconversion. Early intervention was intended to reduce dissemination of HIV not only to the lymphoid organs but also to the central nervous system. However, in this case, neurological symptoms progressed. We treated the patient with high-dose intravenous methylprednisolone to mitigate excessive inflammation. The therapy was so effective that the neurological disorder improved in 3 days. Use of corticosteroids increases the risk of manifestation of an endogenous opportunistic infection. Actually, hepatic amebiasis occurred in this case. Therefore, it is important to pay close attention to the potential development of opportunistic infections with a high-dose corticosteroid treatment. Though the CD4 count decreased to 107/ $\mu$ l after the high dose of the corticosteroid, it recovered to 893/ $\mu$ l in 2 weeks, and HIV level was successfully controlled by HAART. Thus, this clinical study clearly demonstrates that the use of a high dose of corticoids is safe for patients with a primary HIV infection.

This work was supported by the Ministry of Health and Welfare of Japan and by the Organization of Pharmaceutical Safety and Research (OPSR). The authors thank Helen Fraser for her careful reading and editing of the manuscript.

## REFERENCES

1. Niu, M., Stein, D. and Schnittman, S. (1993): Primary human immunodeficiency virus type 1 infection: review of pathogenesis and early treatment intervention in humans and animal retrovirus infection. *J. Infect. Dis.*, 168, 1490-1501.
2. Castellanos, F., Mallada, J., Ricart, C. and Zabala, J. A. (1994): Ataxic neuropathy associated with human immunodeficiency virus seroconversion. *Arch. Neurol.*, 51, 236.
3. Hassin-Baer, S., Steiner, I., Achiron, A., Sadeh, M., Vonsover, A. and Hassin, D. (1998): Unusual neurological manifestations of primary human immunodeficiency virus infection. *Eur. J. Neurol.*, 5: 369-373.
4. Dennig, D. W., Anderson, J., Rudge, P. and Smith, H. (1987): Acute myelopathy associated with primary infection with human immunodeficiency virus. *Br. Med. J.*, 294, 143-144.