

Laboratory and Epidemiology Communications

Highly Active Antiretroviral Therapy for the Treatment of Kaposi's Sarcoma Associated with Primary Human Immunodeficiency Virus Type-1 Infection

Ikumi Genka, Akira Yasuoka, Kiyoshi Saitoh¹ and Shinichi Oka*

AIDS Clinical Center and ¹Department of Pathology, International Medical Center of Japan, Toyama 1-21-1, Shinjuku-ku, Tokyo 162-8655

Communicated by Hiroshi Yoshikura

(Accepted August 1, 2000)

Kaposi's sarcoma (KS) is a well-known symptom of acquired immunodeficiency syndrome. KS can be present in patients with wide-ranging CD4⁺ T cell counts (CD4 count) but becomes increasingly common as immune function declines. Highly active antiretroviral therapy (HAART) consisting of a human immunodeficiency virus type-1 (HIV-1) protease inhibitor in combination with two nucleoside analogues has been shown to decrease the plasma viral load, leading to an increase in the CD4 count. This reconstitution of the immune function has been shown to be an effective treatment for KS and obviates the need for a specific KS therapy (1). In this study, we describe a patient who developed KS shortly after primary HIV-1 infection and who achieved complete remission of the KS lesions by means of HAART.

A 52-year-old homosexual male was admitted to a hospital on May 22, 1998, with a history of headache, fever, muscle weakness of the lower extremities and difficulty in urination. He had sensory disturbances of the face, trunk, both lower extremities, and weakness of both iliopsoas muscles. The cerebrospinal fluid (CSF) showed lymphocyte dominant pleocytosis. He was suspected of having an inflammatory radiculoneuropathy. Starting on June 5, he was treated for 2 weeks with prednisolone at a dose of 60 mg/day, and then doses were decreased by 10 mg every week to reach a dose of 20 mg/day 4 weeks later. The dose was further decreased to 15 mg/day on July 21, and this level was maintained till the medication was stopped. On July 3, his blood and CSF were tested for syphilis using the fluorescent treponemal antibody absorption test; both samples were positive. A diagnosis of neurosyphilis was made; treatment with aqueous crystalline penicillin G was commenced on July 6 and continued for 10 days.

On July 27, he was found to be infected with HIV. HIV-1 RNA in the plasma was 7.5×10^5 copies/ml. His CD4 count was $620/\mu\text{l}$. In Western blot, p24 was detected. He was referred to our hospital on August 11. He had oral candidiasis. Neurological findings were normal. His only medication was prednisolone at a dose of 15 mg/day. On August 11, his CD4 count decreased to $158/\mu\text{l}$, and in Western blot, gp160 and gp41 bands, in addition to the p24 band, became positive. HIV-1 RNA in the plasma remained at 7.5×10^5 copies/ml, however. One month later, hematoma-like tumors appeared in the oral cavity, on the back, on the right side of the chest,

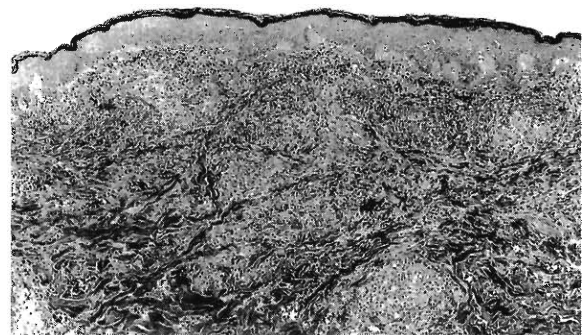


Figure. Hematoxylin and eosin stain ($\times 70$) of a thin section of an early Kaposi's sarcoma on the back (10×5 mm in size). Blood vessels and spindle cells proliferated irregularly in the dermis. Mild erythrocyte extravasation and lymphocyte infiltration were observed. The walls of the blood vessels are thin, and endothelial cells are slightly swelled but not atypical. The spindle cells showed mild atypia, and a few mitotic figures were seen.

and on the lower extremities. These tumors were diagnosed as KS by skin biopsy (Figure). On a visit the following month, the CD4 count was $177/\mu\text{l}$. HIV-1 RNA in the plasma was 8.3×10^5 copies/ml. The p24, gp41, and gp120 bands were positive in Western blot. These results suggested that this patient was experiencing a primary HIV-1 infection.

HAART with zidovudine, lamivudine and indinavir was commenced on October 6, and prednisolone was discontinued on October 20. After 4 months of HAART, the CD4 count increased to $558/\mu\text{l}$ and HIV-1 RNA in the plasma decreased to 560 copies/ml. During this time, the oral KS lesions disappeared, and the anterior chest and leg lesions turned into scars. No specific treatment for KS had been given.

The neurological signs and symptoms seen in this patient included headache, muscle weakness, and lymphocyte dominant pleocytosis of the CSF. Though the symptoms were first attributed to inflammatory neuropathy and late neurosyphilis, they were probably due to a primary HIV-1 infection (2,3). KS is the most common neoplasm affecting HIV-1 infected individuals, particularly in the gay population. The presence of human herpesvirus 8 (HHV-8) (4) and immune-suppression appeared to be important factors for the development of KS (5). It is interesting to note that, in our patient, the incubation time from the infection to the development of

*Corresponding author: Tel/Fax: +81-3-5273-5193, E-mail: oka@imcj.hosp.go.jp

KS lesions was very short, only 4 months. A possible reason for this rapid development of KS lesions was the use of steroids. Progressive KS is usually treated with interferon- α and other cytotoxic drugs (6). However, these therapies often cause myelo- and immune-suppressive side effects. In our case, HAART cured the KS lesions without any serious side effects. Recovery of immune responses produced by antiviral agents probably enabled tumor regression to occur (1,7). HAART should perhaps be the first choice of therapy for early stage KS.

This work was supported by the Ministry of Health and Welfare of Japan. The authors thank Helen Fraser for carefully reading and editing the manuscript.

REFERENCES

1. Dupont, C., Vasseur, E., Beauchet, A., Aegerter, P., Berthe, H., de Truchis, P., Zucman, D., Rouveix, E. and Saiag, P. on behalf of CISIH 92 (2000): Long-term efficacy on Kaposi's sarcoma of highly active antiretroviral therapy in a cohort of HIV-positive patients. *AIDS*, 14, 987-993.
2. Tindall, B. and Cooper, D. A. (1991): Primary HIV infection: host responses and intervention strategies. *AIDS*, 5, 1-13.
3. Tindall, B., Baker, S., Donovan, B., Barnes, T., Roberts, J., Kronenberg, C., Gold, J., Penny, R. and Cooper, D. A. (1988): Characterization of the acute clinical illness associated with human immunodeficiency virus infection. *Arch. Intern. Med.*, 148, 945-949.
4. Chang, Y., Cesarman, E., Pessin, M. S., Lee, F., Culpepper, J., Knowles, D. M. and Moore, P. S. (1994): Identification of herpesvirus like DNA sequences in AIDS-associated Kaposi's sarcoma. *Science*, 226, 1865-1869.
5. Antiman, K. and Chang, Y. (2000): Kaposi's sarcoma. *N. Engl. J. Med.*, 342, 1027-1038.
6. Yarchoan, R. (1999): Therapy for Kaposi's sarcoma: recent advances and experimental approaches. *J. Acquir. Immune Defic. Syndr.*, 21, Suppl. 1, 66-73.
7. Parra, R., Leal, M., Delgado, J., Macias, J., Rubio, A., Gomez, F., Soriano, V., Sanchez-Quijiano, A., Pineda, J. A. and Lissen, E. (1998): Regression of AIDS-related Kaposi's sarcoma following antiretroviral therapy. *Clin. Infect. Dis.*, 26, 218-219.