

Laboratory and Epidemiology Communications

A Queensland Koala Kept in a Japanese Zoological Park was Carrier of an Imported Fungal Pathogen, *Filobasidiella neoformans* var. *bacillispora* (*Cryptococcus neoformans* var. *gattii*)

Koichi Makimura^{1,2*}, Mizuki Karasawa³, Humio Hosoi³, Toshiki Kobayashi³, Nanako Kamijo³, Kazuhiro Kobayashi³, Hiroshi Hiramatsu³, Takako Akikawa³, Tomoko Yabe³, Ayumi Yamaguchi³, Osamu Ishida³, Arisa Murakami¹, Ryuichi Fujisaki¹, Yayoi Nishiyama^{1,2}, Katsuhisa Uchida¹ and Hideyo Yamaguchi^{1,2}

¹Teikyo University Institute of Medical Mycology and

²Genome Research Center, Teikyo University,
359 Otsuka, Hachioji, Tokyo 192-0395 and

³Tama Zoological Park,
Hodokubo 7-1-1, Hino-shi, Tokyo 191-0042

Communicated by Hiroshi Yoshikura

(Accepted April 8, 2002)

Filobasidiella neoformans var. *bacillispora* (anamorph: *Cryptococcus neoformans* var. *gattii*) (1) was isolated from a Queensland koala (*Phascolactus cinereus adustus*) kept in a zoological park in Japan. To our knowledge, this is first isolation of the variant yeast from an animal or human resident in Japan.

A four-year-old male koala (born in the Taronga Zoo, Australia) died of various neurological disorders, including exophthalmos and swelling of the back of the left eye (Fig. 1) and appetite loss. Yeasts were isolated as pure cultures from nose discharge and autopsy materials (brain, nasal cavity, and lung), and diagnosed as *Cryptococcus neoformans* on the basis of the characteristic thick capsules. Examination by an assimilation test, serological test, and molecular biological test (2) revealed that the yeasts were *F. neoformans* var. *bacillispora*.

Cryptococcosis is one of the four life-threatening, deep-seated fungal infections (pulmonary cryptococcosis, meningoencephalitis, etc.) in Japan, and the infection is generally acquired by inhalation. This species of basidiomycetous yeast has two varieties: a Japanese domestic variety, *F. neoformans* var. *neoformans* (serotypes A and D) (3) and one known only as an imported mycoses-causing variety, *F. neoformans* var. *bacillispora* (serotypes B and C) (4). The endemic area of *F. neoformans* var. *bacillispora* infection is geographically restricted to tropical countries including Australia, Brazil, Southern California, Thailand, and others (1).

The clinical features of the cryptococcosis caused by the two varieties are similar, but infection due to *F. neoformans* var. *bacillispora* tends to require lengthy antifungal treatment, and is associated with more neurological sequelae than that due to *F. neoformans* var. *neoformans* (1). Therefore, from a clinical point of view, differentiation diagnosis of the two agents is important.

F. neoformans var. *neoformans* is present in pigeon droppings, a major source of infection, but *F. neoformans* var. *bacillispora* is not, as it is thermosensitive and cannot survive in pigeon

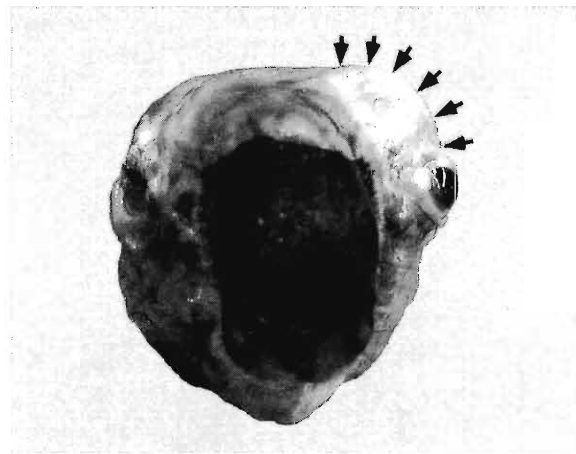


Fig. 1. Frontal view of decorticated head. Exophthalmos of left eye and swelling of the back of eye (arrows) were observed.

intestine (1). In the endemic area, this yeast has been isolated from red gum trees (*Eucalyptus* spp.) (1), rotting trees (5), and animals including koala (1). In the present case, the fungus was not isolated from the cage, its surroundings, red gum trees provided as feed, or the zookeepers who had been taking care of the koala. Five other koalas kept in the same cage were free of the symptoms of the infection. Therefore, the risk of the spread of the infection appeared low in the zoological park. It should be noted also that deep-seated mycoses including cryptococcosis are not usually transmitted from animal to human or human to human. The koala probably acquired the infection in the Taronga Zoo in Australia, where it was born. The details of the present case will be reported elsewhere.

This study was partly supported by Health Science Research Grants for Research on Emerging and Re-emerging Infectious Diseases from Ministry of Health, Labour and Welfare of Japan.

*Corresponding author: Tel: +81-426-78-3256, Fax: +81-426-78-3256, E-mail: makimura@main.teikyo-u.ac.jp

REFERENCES

1. Sorrell, T. C. (2001): *Cryptococcus neoformans* variety *gattii*. *Med. Mycol.*, 39, 155-168.
2. Makimura, K., Tamura, Y., Mochizuki, T., Hasegawa, A., Tajiri, Y., Hanazawa, R., Uchida, K., Saito, H. and Yamaguchi, H. (1999): Phylogenetic classification and species identification of dermatophyte strains based on DNA sequences of nuclear ribosomal internal transcribed spacer I regions. *J. Clin. Microbiol.*, 37, 920-924.
3. Kohno, S., Varma, A., Kwon-Chung, K. J. and Hara, K. (1994): Epidemiology studies of clinical isolates of *Cryptococcus neoformans* of Japan by restriction fragment length polymorphism. *J. Jpn. Assoc. Infect. Dis.*, 68, 1512-1517.
4. Tsunemi, T., Kamata, T., Fumimura, Y., Watanabe, M., Yamawaki, M., Saito, Y., Kanda, T., Ohashi, K., Suegara, N., Murayama, S., Makimura, K., Yamaguchi, H. and Mizusawa, H. (2001): Immunohistochemical diagnosis of *Cryptococcus neoformans* var. *gattii* infection in chronic meningoencephalitis: the first case in Japan. *Intern. Med.*, 40, 1241-1244.
5. Fortes, S. T., Lazera, M. S., Nishikawa, M. M., Macedo, R. C. and Wanke, B. (2001): First isolation of *Cryptococcus neoformans* var. *gattii* from a native jungle tree in the Brazilian Amazon rainforest. *Mycoses*, 44, 137-140.