

Short Communication

Pulmonary Actinomycosis Mimicking Chest Wall Tumor in a Child

Faruk Güçlü Pınarlı*, Birgül Mutlu, Çetin Çelenk¹, Levent Yıldız²,
Murat Elli, Ayhan Dağdemir and Sabri Acar

*Department of Pediatric Oncology, ¹Department of Radiology and
²Department of Pathology, Medical Faculty, Ondokuz Mayıs University, Samsun, Turkey*

(Received March 14, 2005. Accepted May 30, 2005)

SUMMARY: Actinomycosis is an uncommon disease in children and most cases are cervicofacial infections. To date, there have been only a few reports on children with chest wall involvement due to actinomycosis. Here we report a 9-year-old girl with a mass lesion in the chest wall mimicking Ewing's sarcoma of the rib. Thoracic actinomycosis without typical features of the disease is often evaluated with the suspicion of neoplasia. This rare entity should be considered in the differential diagnosis of mass lesions of the chest wall in children. The disease responds well to penicillin treatment.

Thoracic actinomycosis is an uncommon entity (1,2). The disease is usually manifested as a slow progressive pulmonary or mediastinal mass, sometimes with the classic manifestation of draining chest wall sinuses (1,3). To date, there have been only a few reports on children with chest wall involvement due to actinomycosis (4-6). These patients are often investigated with the suspicion of neoplasia. Here, we report a 9-year-old girl with a mass lesion in the chest wall mimicking Ewing's sarcoma of the rib.

The patient was admitted to our hospital with a 3-month history of left-sided chest pain, fatigue and loss of appetite. She had been diagnosed with pneumonia and treated with intravenous antibiotics for 14 days, and her parents noticed a mass lesion 15 days before she was admitted to our hospital. A diagnosis of mediastinal mass was made and the patient was referred to our pediatric oncology center after incisional biopsy of the mass, which was not diagnostic. Unfortunately, no cultures were obtained. Physical examination revealed multiple anterior cervical lymph nodes of <1 cm and a 6 × 7 cm soft tissue mass on the left anterior chest wall. No caries were observed in the teeth. Initial posterior anterior (PA) chest X-ray demonstrated homogenous consolidation of the left middle to upper lung areas and right perihilar nodular consolidation (Fig. 1). Contrast-enhanced computed tomography (CT) of the thorax obtained at the level of the left hilus and pulmonary truncus revealed a soft tissue mass at the left anterior mediastinal region, left upper and middle zones, left anterior thorax wall, and a 2-cm nodular opacity at the right perihilar anterior localization (Fig. 2). Laboratory investigations showed hemoglobin levels of 11 g dl⁻¹, a leukocyte count of 13,000/mm³ with a differential of 60% polymorphonuclear leukocytes, 24% lymphocytes, 10% monocytes, 6% eosinophils and a platelet count of 503,000/mm³. The patient's erythrocyte sedimentation rate (ESR) was 44 mm/h, serum LDH was 282 U L⁻¹, and CRP was 4.6 mg dl⁻¹. Serum electrolytes, blood urea nitrogen (BUN), creatinine, serum glutamic oxaloacetic transaminase (SGOT) and serum glutamic pyruvic transaminase (SGPT) were all between

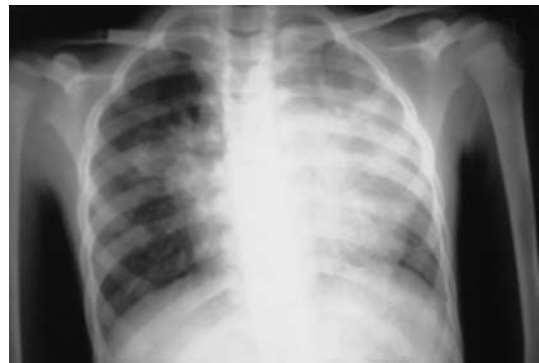

Fig. 1. PA chest X-ray: left upper and middle zone homogenous and right perihilar nodular consolidation.

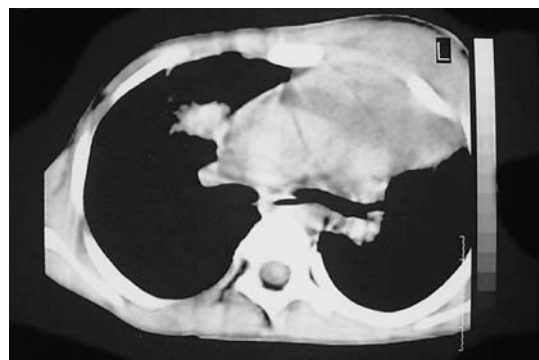

Fig. 2. Contrast-enhanced CT scan of the thorax obtained at the level of the left hilus and pulmonary truncus shows a soft tissue mass at the left anterior mediastinal region, left upper and middle zones, left anterior thorax wall, and a 2-cm nodular opacity at the right perihilar anterior localization.

normal limits. Purified protein derivative (PPD) for a tuberculous skin test was non-reactive and cultures for *Mycobacterium tuberculosis* were negative. Bone marrow aspiration showed no tumoral infiltration. Reexamination of the incisional biopsy showed fibrous connective tissue with intense mixed inflammatory cells and vascular proliferation. *Actinomyces* colonies were observed in necrotic exudative masses consisting of polymorphonuclear leukocytes and

*Corresponding author: Mailing address: Atatürk Bulvarı no: 80, Akyüz sitesi A Blok 2 daire: 21, 55200 Samsun, Turkey. Tel: +90-362-3121919 int. 3324, Fax: +90-362-4576041, E-mail: gfpinarli1@ttnet.net.tr

histiocytes (Fig. 3). A diagnosis of pulmonary actinomycosis was made and penicillin G 250,000 U/kg was started. Magnetic resonance imaging of the thorax showed a significant reduction in the mass and the pectoral muscle infiltration after 3 weeks of treatment (Fig. 4) and the patient was completely asymptomatic at that time. Penicillin treatment was continued as penicillin V 100,000 U/kg/day for 6 months.

Actinomycosis is an uncommon disease in children caused by *Actinomyces*, a slow-growing, Gram-positive, microaerophilic bacterium. *Actinomyces israelii* is the predominant microorganism causing actinomycosis in humans. Most cases are cervicofacial infections; intrathoracic disease is rare (2-4). *Actinomyces* is a normal saprophyte of the oral cavity and nasopharynx, and pulmonary actinomycosis is caused by aspiration or inhalation of infected oropharyngeal secretions; mediastinal and chest wall involvement is probably the result of direct extension from the lungs. Nevertheless, we found no risk factors such as antecedent disease, surgery, dental caries, inhalation injury, swallowing problems for aspiration of oral materials or pre-existing cervicofacial or abdominal disease in our patient.

Neither the patient's clinical nor radiographic features were specific for thoracic actinomycosis. The most common symptoms are pleuritic pain, cough, fever, sputum production, hemoptysis and weight loss (1-2,7-8). The symptoms in the present case were not initially diagnostic for pulmonary actinomycosis and the patient was treated for non-specific pneumonia. Later, the infection frequently dissects along tissue planes and may extend through the chest wall, producing sinus tracts with small abscesses and purulent drainage. The disease may be complicated by bony destruction of the adjacent ribs, sternum and vertebral bodies (7). The triad of

chronic consolidation, pleural effusion and rib periostitis may indicate the disease (4). Although abscess formation in the chest wall is an important clue for the diagnosis (5), the classic manifestations of pulmonary infiltrates and draining chest wall sinuses with a characteristic yellow granular discharge is not always evident. Thoracic actinomycosis lacking classic signs may mimic tuberculosis (9) or neoplasias such as leukemia, lymphoma, Langerhans cell histiocytosis or solid tumors, and patients are evaluated for suspicion of malignancy (3,10,11). In our patient, the subsequent chest wall mass after initial symptoms alerted the clinician to the possibility of a tumor. The roentgenographic manifestations of actinomycosis include patchy pulmonary infiltrates, pleural and pericardial effusions, cavitary or mass lesions and rib changes (1,12). In the present case, important clues for diagnosis included consolidation of the left lung with a soft tissue mass at the mediastinum and chest wall. The final diagnosis depends on bacterial culture or histopathologic examination (7), which required a tissue sampling in our patient.

In conclusion, thoracic actinomycosis should be considered in the differential diagnosis of mass lesions, especially when preceded by pneumonia, even in the absence of typical features such as draining sinuses. Once the diagnosis is made, parenteral penicillin G treatment for 2-6 weeks followed by oral penicillin V for 3-12 months is highly effective, and complete recovery is generally achieved (7).

REFERENCES

1. Spinola, S. M., Bell, R. A. and Henderson, F. W. (1981): Actinomycosis. A cause of pulmonary and mediastinal mass lesions in children. *Am. J. Dis. Child.*, 135, 336-339.
2. Lee, J. P. and Rudoy, R. (2003): Pediatric thoracic actinomycosis. *Hawaii Med. J.*, 62, 30-32.
3. Benammar, S., Helardot, P. G., Sapin, E., Adamsbaum, C. and Raymond, J. (1995): Childhood actinomycosis: report of two cases. *Eur. J. Pediatr. Surg.*, 5, 180-183.
4. Wilson, D. C. and Redmond, A. O. (1990): An unusual cause of thoracic mass. *Arch. Dis. Child.*, 65, 991-992.
5. Bark, B., Perlick, E. and Stover, B. (2004): Thoracic wall crossing (pseudo-?) tumor in a child: abscess-forming thoracic actinomycosis caused by *Actinomyces meyeri et israelii*. *Rofo*, 176, 125-127.
6. Hachitanda, Y., Nakagawara, A. and Ikeda, K. (1989): An unusual anterior chest wall tumor due to actinomycosis in a child. *Pediatr. Radiol.*, 20, 96.
7. Jacobs, R. F. and Schutze, G. E. (2004): Actinomycosis. p. 892-894. *In* Behrman, R. E., Kliegman, R. M. and Jenson, H. B. (ed.), *Nelson Textbook of Pediatrics*. Chapter 174. Saunders, Philadelphia.
8. Lu, M. S., Liu, H. P., Yeh, C. H., Wu, Y. C., Liu, Y. H., Hsieh, M. J. and Chen, T. P. (2003): The role of surgery in hemoptysis caused by thoracic actinomycosis; a forgotten disease. *Eur. J. Cardiothorac. Surg.*, 24, 694-698.
9. Goussard, P., Gie, R., Kling, S. and Beyers, N. (1999): Thoracic actinomycosis mimicking primary tuberculosis. *Pediatr. Infect. Dis. J.*, 18, 473-475.
10. Wu, C. Y. and Li, Y. W. (1993): Multifocal thoracic actinomycosis simulating lymphoma. *Pediatr. Radiol.*, 23, 541-542.
11. Watt, A. J. (2002): Chest wall lesions. *Paediatr. Respir.*

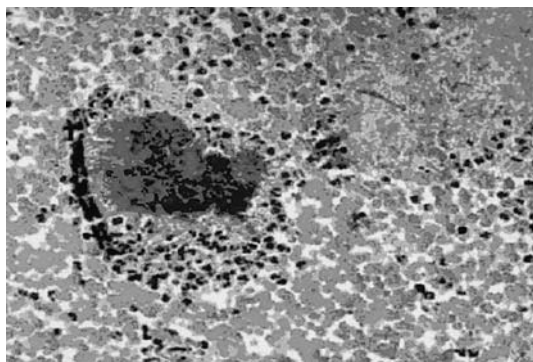


Fig. 3. Colony of *Actinomyces* composed of branching filaments with a radial pattern in microabscess foci surrounded by purulent exudates.

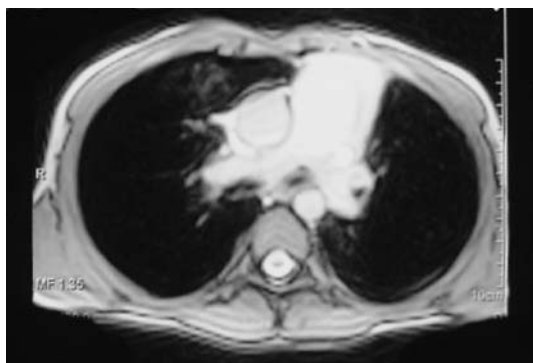


Fig. 4. Axial T2-weighted spin-echo MR imaging of the thorax show no abnormality.

Rev., 3, 328-338.

12. Ng, K. K., Cheng, Y. F., Ko, S. F., Ng, S. H., Pai, S. C. and Tsai, C. C. (1992): CT findings of pediatric thoracic

actinomycosis: report of four cases. J. Formos. Med. Assoc., 91, 346-350.