

Original Article

Investigation of an Outbreak of Scrub Typhus in the Himalayan Region of India

Anuradha Sharma*, Sanjay Mahajan¹, M. L. Gupta, Anil Kanga and Vijay Sharma

*Department of Microbiology and ¹Department of Medicine,
Indira Gandhi Medical College and Hospital, Himachal Pradesh, India*

(Received May 18, 2004. Accepted March 22, 2005)

SUMMARY: In Indira Gandhi Medical College, Himachal Pradesh, India, during autumn of 2003 (September–November), more than 100 cases of fever of unknown origin (FUO) were reported with 15 ensuing deaths. In addition to all routine investigations and cultures, the Weil-Felix test was incorporated for the investigation of these cases. Antigen was procured from the Central Research Institute, Kasauli. Forty-six percent (45/96) of the cases demonstrated a $\geq 1:80$ titer of agglutinins against OXK antigen. A team from the National Institute of Communicable Diseases, New Delhi, confirmed the antibodies for scrub typhus in some of the serum samples tested for leptospirosis, dengue fever, and rickettsial infections. Twelve blood samples positive for OXK antigen were sent to the Defense Research Development Establishment, Gwalior, for polymerase chain reaction studies, but none of the samples were positive, as all of the patients were already on broad-spectrum antibiotics and had reported to our hospital after 7–10 days of fever. At our institute, the Weil-Felix test has now been routinely introduced for the investigation of cases of FUO, and the results until April 2004 (150 cases) revealed the presence of other rickettsial infections prevalent in the region. To evaluate the epidemiology and magnitude of the problem, further prospective studies are required.

INTRODUCTION

Of all of the afflictions of the human race, the rickettsial diseases rank among the foremost as a cause of suffering and death. The record of deaths from epidemic typhus in the last century in the Balkan countries, Poland, and Russia reached astounding figures (1). Rickettsial diseases (typhus and spotted fever group, scrub typhus, and Q fever) may pose a serious public health problem, primarily when they are underdiagnosed or misdiagnosed (2).

During September to November of 2003, there were more than 100 cases of fever of unknown origin (FUO) admitted to the Indira Gandhi Medical College and Hospital (IGMC), Shimla, Himachal Pradesh (Himalayan Region), India. The patients were investigated using all routine diagnostic tests and cultures. The Weil-Felix test was introduced for the investigation of rickettsial diseases, which are endemic in the Himalayan Mountains (1). A team from the National Institute of Communicable Diseases (NICD) (reference laboratory), New Delhi, collected serum samples from 31 cases of FUO and a battery of tests was utilized to exclude leptospirosis, dengue fever, and rickettsial infections (3). The results showed that 11 (35%) samples were positive for antibodies against scrub typhus. Twelve blood samples showing antibodies against OXK antigen were also sent for polymerase chain reaction (PCR) studies to the Defense Research Development Establishment (DRDE), Gwalior. Since scrub typhus is a reemerging infection with the possibility of drug resistance, both the epidemiology and magnitude of the problem need to be evaluated (4).

MATERIALS AND METHODS

The Weil-Felix test was introduced at our institute with

the outbreak of FUO. The antigen was procured from the Central Research Institute (CRI), Kasauli, Himachal Pradesh. This antigen is standardized with *Proteus* agglutinating serum supplied by Wellcome Diagnostics, Dartford, England. Patient sera were tested by the tube agglutination method with a doubling dilution of 1:20 to 1:640, and a titer of $\geq 1:80$ or a fourfold rise in titer was considered positive (3). Until April 2004, a total of 150 serum samples were tested at our institute using the Weil-Felix test.

Twelve blood samples in EDTA were sent to the DRDE for PCR studies. DNA was extracted using a blood genomic DNA kit (Sigma, St. Louis, Mo., USA). PCR was performed with *Orientia* specific primers Ot 34 and Ot 56 (5).

RESULTS

During the period between September 2003 to April 2004, a total of 150 cases were tested with the Weil-Felix test, among which, 52 cases were positive for OXK antigen (Fig. 1). During the outbreak in autumn alone (September–November 2003), a total of 45 cases were found to be positive for this antigen from among 96 cases (46.5%). Most of the serum samples showed a titer of $\geq 1:160$. A fourfold rise in titer was demonstrated in cases in which subsequent serum samples were submitted, and the highest titer was $\geq 1:2560$. During the initial outbreak, 40 adults and 5 children were affected. Among adults, the male:female ratio was 1:1.5 (16/24). The most common presenting signs were lymphadenopathy (44.4%) and splenomegaly (37.7%). In only three cases, eschar was seen. In 13 (28.8%) cases, liver function tests were abnormal, although jaundice was seen in only four cases. The present study reports 15 deaths, all adults; the usual cause was pneumonitis, whereas in some cases, encephalitis or acute renal failure was responsible.

Some samples were also positive for OX2 and OX19 antigens (Table 1 and Fig. 1). A total of 26 cases were positive for OX2 and 6 cases were positive for OX19. Antibodies were seen in 13 cases against OX2 only, in 5 cases against OX2

*Corresponding author: Mailing address: Mohindra Apartments, Nav-Bahar, Shimla-171002, Himachal Pradesh, India. Tel: +91-177-2640563, E-mail: dr_anu03@yahoo.co.in

Table 1. Results of the Weil-Felix test showing number of patients for each titer

Titer	OX2	OX19	OXK
1:40	33	7	9
1:80	18	5	20
1:160	6	1	22
1:320	2	0	10

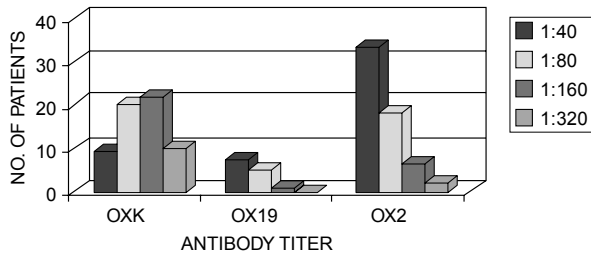


Fig. 1. Results of the Weil-Felix test. Distribution of patients ($n = 150$) for antibody titer of OXK, OX19, and OX2 antigens of the Weil-Felix test.

and OX19, and in 8 cases against OX2 and OXK. The majority of the cases positive for OX19 were seen during January and February of 2004.

PCR analysis did not reveal the expected amplicon of 1031 base pairs in any of the 12 samples.

DISCUSSION

Scrub typhus is endemic in Southeast Asia, Northern Australia, and the Islands of the Western Pacific Ocean, and thus it is seen from sandy beaches to the Himalaya Mountains. Indigenous rural workers, residents of suburban areas, and westerners visiting endemic areas for military, business and recreational purposes are most commonly infected (1). In the present study, a recent outbreak, most notably in autumn of 2003, is described. Mathai et al. reported an outbreak of scrub typhus in southern India during the cooler months from October 2001 to February 2002 (4). Singh reported that in India, the disease had occurred among troops during World War II in Assam and West Bengal, and in the 1965 Indo-Pak war. There was a resurgence of the disease in 1990 in a unit of an army deployed at the Pakistan border of India (6).

In the outbreak described here, most patients were from a rural background, and most of the districts of the state were involved. Females were more affected than males because they more commonly worked in the fields. Park et al. observed in their study that in an outbreak in Korea, females were more commonly infected, i.e., the ratio of females to males was 3.4:1 (7). Watt et al. reported that in Thailand, leptospirosis and scrub typhus were associated with rice farming (8).

The classical case description is an eschar at the site of the bite, as well as regional lymphadenopathy and a maculopapular rash, but these signs are seldom evident. Usually a fever that lasts about 2 weeks, a cutaneous rash which develops on or around the 5th day, and the appearance of agglutinins against the OXK antigen late in the 2nd week are seen (1). Incubation period is 1 to 3 weeks, but in our study, a history of contact with mites was usually not available. Park et al. recommend including scrub typhus in the

differential diagnosis of autumn season febrile hepatic disease, as their patients usually showed raised AST, ALT, and GGTP levels, but had normal total bilirubin levels (7). The outbreak described here occurred in autumn; many patients presented with abnormal liver function tests. Aronoff and Watt found a prevalence of relative bradycardia in 53% cases (9). According to G. Watt, a history of hearing loss coincident with the onset of fever is an uncommon but specific symptom of scrub typhus (unpublished data) (8).

In the outbreak described here, one case was HIV-infected, but no difference in the severity of infection was observed. Kantipong et al. noted that unlike some other intracellular pathogens, *Orientia tsutsugamushi* does not cause an unusually severe infection in AIDS patients (10). Among the patients reported here, five females were pregnant (vertical transmission is known) (11). Suntharasaj et al. reported fetal jeopardy in a pregnant woman with scrub typhus at 34 weeks, and Caesarean section was performed to save the baby. The neonate suffered hepatosplenomegaly, and IgM antibodies were detected against scrub typhus in both the mother and child (12). In the outbreak discussed here, most of the pregnant women were in the second trimester and were from the periphery of Shimla, and therefore outcome of pregnancy was not known in these cases.

Severe cases typically present with prominent encephalitis and pneumonitis as the key features of vascular injury (1). In this outbreak, most cases succumbed due to respiratory involvement. Watt et al. reported that the most common cause of death in scrub typhus was adult respiratory distress syndrome (ARDS) (8). In untreated classical cases, mortality is usually 7%; however, the figure would probably be lower if all relatively mild cases were also included in the total cases studied. Infection is more prevalent than the clinical diagnosis would suggest. Apart from leptospirosis and dengue fever, other infections such as typhoid, malaria, measles, meningococcal infections, and other rickettsial infections should be included in the differential diagnosis of scrub typhus (1).

In this outbreak, all patients who presented early responded to tetracycline. Azithromycin was given to pregnant women and pediatric patients (11). For seriously ill patients, intravenous chloramphenicol is advised (8).

The diagnosis of rickettsial diseases was greatly aided when Weil and Felix discovered in 1916 that patient sera agglutinated certain Proteus antigens. The Weil-Felix reaction is still widely used, but has been gradually replaced by more accurate and sensitive methods (13). Although *Rickettsiae* can be isolated from clinical specimens, the isolation of the organism in the laboratory is not done in routine because it requires a containment level 3. PCR amplification of DNA from the blood of febrile patients is available in reference laboratories (1). Serological tests still remain an indispensable tool. Microimmunofluorescence test is considered the best approach, followed by latex agglutination (LA), indirect hemagglutination (IHA), immunoperoxidase assay (IPA), and enzyme linked immunosorbent assay (ELISA). The ELISA is suitable for seroepidemiological studies. Immunoblot analysis can be used to confirm the results of other tests. The use of the Weil-Felix test should be reserved only for situations in which other serological tests are not available (2).

Extensive reports on the use of the Weil-Felix test have indicated that it detects many more positive cases than are misdiagnosed (14). Broadly, the Weil-Felix test does provide at least some clues regarding the nature of the infection, which

can be cross-confirmed using other techniques, if available (15). PCR can serve as a useful and convenient alternative in such situations. Here, we had also sent some blood samples for PCR amplification to the DRDE and no amplification was observed. The reason for this result could be that all of the patients had reported to our hospital after 7-10 days of fever and they already been administered broad-spectrum antibiotics. Some recent reports have suggested that PCR findings can be positive, even in treated patients (16); however, Murai et al. reported that PCR results become negative after the administration of antibiotics, and this finding has been used for monitoring the prognosis of the disease (17).

Positive sera for OX2 and OX19 antigens have indicated the prevalence of other rickettsial infections (typhus fever and spotted fever group) in the region. From this study, we conclude that in the Himalayan Region, rickettsial infections should be included in the differential diagnosis of all cases of FUO. There is still an urgent need for additional prospective studies.

ACKNOWLEDGMENTS

The authors are grateful to the Director, DRDE, Gwalior; Director, NICD, New Delhi; Director, CRI, Kasauli; and the Principal, IGMC, Shimla for their guidance, support and encouragement.

The authors would also like to acknowledge the funding agency Defense Research Development Organization of the Ministry of Defense, Government of India, for their support.

REFERENCES

- Woodward, E. T. (2000): Rickettsial diseases. *In* K. J. Isselbacher, E. Braunwald, J. D. Wilson, J. B. Martin, A. S. Fauci and D. L. Kasper (eds.), *Harrison's Principles of Internal Medicine*. McGRAW-HILL, Inc., New York.
- Kovacova, E. and Kazar, J. (2000): Rickettsial diseases and their serological diagnosis. *Clin. Lab.*, 46, 239-245.
- Marmion, B. P. and Worswick, D. A. (1996): *Coxiella burnetii* and other medically important members of the family *Rickettsiaceae*. *In* J. G. Collee, B. P. Marmion, A. G. Fraser and A. Simmons (eds.), *Mackie & McCartney Practical Medical Microbiology*. Churchill Livingstone, New York.
- Mathai, E., Rolain, J. M., Verghese, G. M., Abraham, O. C., Mathai, D., Mathai, M. and Raoult, D. (2003): Outbreak of scrub typhus in southern India during the cooler months. *Ann. N. Y. Acad. Sci.*, 990, 359-364.
- Furuya, Y., Yoshida, Y. and Katayama, T. (1991): Specific amplification of *Rickettsia tsutsugamushi* DNA by nested polymerase chain reaction. *J. Clin. Microbiol.*, 29, 2626-2628.
- Singh, P. (2004): Scrub typhus, a case report: military and regional significance. *Med. J. Armed Forces India*, 60, 89-90.
- Park, J. I., Han, S. H., Cho, S. C., Jo, Y. H., Hong, S. M., Lee, H. H., Yun, H. R., Yang, S. Y., Yoon, J. H., Yun, Y. S., Moon, J. Y., Cho, K. R., Baik, S. H., Son, J. H., Kim, T. W. and Lee, D. H. (2003): Outbreak of hepatitis by *Orientia tsutsugamushi* in the early years of the new millennium. *Korean J. Hepatol.*, 9, 198-204 (in Korean).
- Watt, G., Jongsakul, K. and Suttinont, C. (2003): Possible scrub typhus coinfections in Thai agricultural workers hospitalized with leptospirosis. *Am. J. Trop. Med. Hyg.*, 68, 89-91.
- Aronoff, D. M. and Watt, G. (2003): Prevalence of relative bradycardia in *Orientia tsutsugamushi* infection. *Am. J. Trop. Med. Hyg.*, 68, 477-479.
- Kantipong, P., Watt, G., Jongsakul, K. and Choenchitra, C. (1996): Infection with human immunodeficiency virus does not influence the clinical severity of scrub typhus. *Clin. Infect. Dis.*, 23, 1168-1170.
- Shandera, W. X. and Shelburne, S. A. (2003): Infectious diseases: viral and rickettsial. p. 1340-1341. *In* L. M. Tierney, S. J. McPhee and M. A. Papadakis (eds.), *Current Medical Diagnosis & Treatment 2003*. Lange Medical Books/McGRAW-HILL Medical Publishing Division, New York.
- Suntharasaj, T., Janjindamai, W. and Krisanapan, S. (1997): Pregnancy with scrub typhus and vertical transmission: a case report. *J. Obstet. Gynaecol. Res.*, 23, 75-78.
- Dasch, G. A. and Weiss, E. (1998): The Rickettsiae. p. 854. *In* L. Collier, A. Balows and M. Sussman (eds.), *Topley & Wilson's Microbiology & Microbial Infections* vol. 2. Publishers Arnold, London.
- Suzuki, T. and Eto, M. (1980): The value of Weil-Felix test on the diagnosis of tsutsugamushi diseases. *Jpn. Med. News*, 2956, 43-47.
- La Scola, B. and Raoult, D. (1997): Laboratory diagnosis of rickettsioses: current approaches to diagnosis of both old and new rickettsial diseases. *J. Clin. Microbiol.*, 35, 2715-2727.
- Watchere, S., Chenchittikul, M. and Silpapojakul, K. (2004): Evaluation of nested PCR for the diagnosis of scrub typhus among patients with acute pyrexia of unknown origin. *Trans. R. Soc. Trop. Med. Hyg.*, 98, 360-366.
- Murai, K., Okayama, A., Horinouchi, H., Hoshikawa, T., Tachibana, N. and Tsubouchi, H. (1995): Eradication of *Rickettsia tsutsugamushi* from patients blood by chemotherapy, as assessed by the polymerase chain reaction. *Am. J. Trop. Med. Hyg.*, 52, 325-327.