

Original Article

A Pediatric Case of Disseminated Cystic Echinococcosis Successfully Treated with Mebendazole

Zühre Kaya* and Türkiz Gürsel¹

¹Division of Hematology, Department of Pediatrics, Medical School of Gazi University, Ankara, Turkey

(Received July 30, 2003. Accepted December 26, 2003)

SUMMARY: We report a 4-year-old girl with disseminated cystic echinococcosis in the lung and the liver and a solitary cyst in the left kidney. Mebendazole therapy produced complete resolution of the lung and kidney cysts. In the liver, most of the smaller cysts disappeared, whereas the larger cysts showed only partial response and required surgical excision. Our experience reinforces the finding in previous reports that long term medical treatment of cystic echinococcosis with mebendazole can be lifesaving in cases that are unmanageable by surgical treatment.

INTRODUCTION

Cystic echinococcosis (CE) is a serious health problem in endemic countries including Turkey and many other Mediterranean countries (1-3). It is caused by *Echinococcus granulosus*, which enters portal circulation from the upper intestine and lodges in the liver, the lung, and other organs and tissues where it develops into cysts. Although surgery is still widely practiced for most patients with CE, medical therapy with benzimidazoles (mebendazole or albendazole) either alone or in conjunction with surgery has been reported to be effective in a significant percentage of patients (4-7). However, the safety and efficacy of mebendazole in young children with CE is limited (8,9). We herein report a pediatric case of a rare form of disseminated CE affecting the lung, the liver, and the kidney that was successfully managed with mebendazole without side effects.

PATIENT AND LABORATORY INFORMATION

A 4-year-old girl presented with fever, cough, abdominal pain, and weight loss of 2 months duration. She was living on a farm and had close contact with dogs and sheep. Physical examination showed malnutrition and a body weight in the less than the 25th percentile, diminished breath sounds, and massive hepatomegaly of 10 cm palpable below the right costal margin.

Laboratory investigations including complete blood count, urine analysis, and blood chemistry gave normal results excepting 8% eosinophilia on white blood cell differential. Anterior-posterior chest x-ray showed shadows of numerous cysts of similar size (2-3 cm) filling both lung fields (Figure 1A). An abdominal ultrasound examination revealed widespread cystic lesions ranging in diameter from 1 mm to 20 mm in both lobes of the liver and one large cyst 3 cm in diameter in the left kidney (Figure 2A). Indirect hemagglutination test for cyst hydatid was positive in 1/3,200 titer (1,10).

*Corresponding author: Mailing address: Birlik mahallesi, 68. Sokak, No:16/4, Çankaya, Ankara 06610, Turkey. Tel: +90 312 214 10 00 ext. 6038-6012, Fax: +90 312 213 49 70, E-mail: zuhre_kaya@yahoo.com

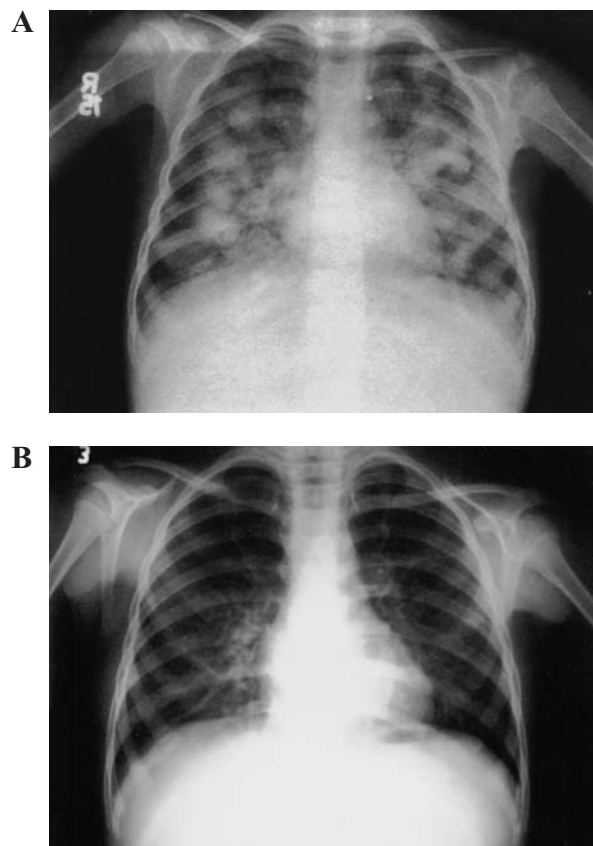


Fig. 1. Chest x-ray. Widespread cysts before (A) and 13 months after (B) mebendazole treatment.

RESULTS

Mebendazole was commenced at 40 mg/kg per day in three divided doses. Complete blood count with leukocyte differential, liver and kidney function tests, and chest x-ray were repeated weekly during the first month and twice in the second month. Abdominal ultrasonography was repeated monthly. Marked reduction in cyst size was noted at the end of the first few months of mebendazole therapy, and was more pronounced in the lung and kidney cysts than in those in the liver. The lung and kidney cysts had completely disappeared at the 13th month (Figure 1B). Most of the liver cysts also

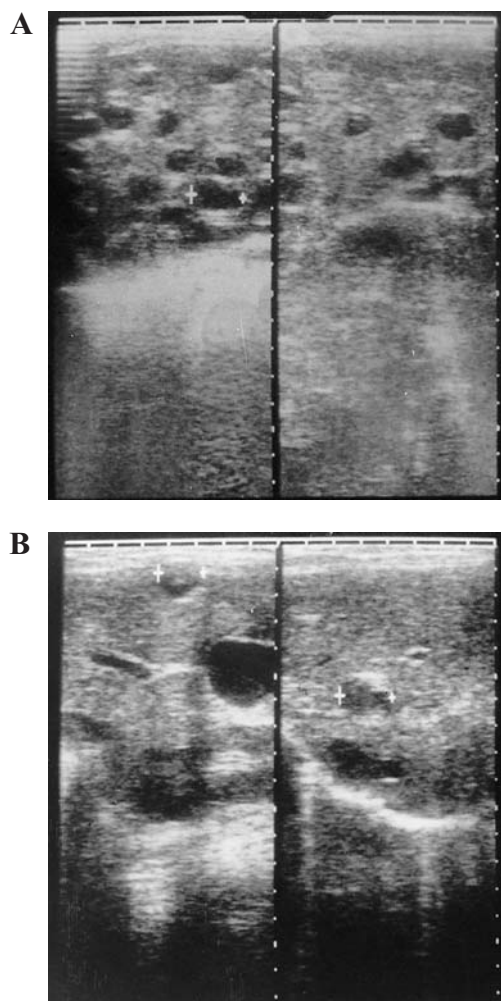


Fig. 2. Abdominal ultrasonography. Multiple liver cysts before (A) and 20 months after (B) mebendazole treatment. (Note that some of the smaller cysts disappeared or shrank with treatment whereas two cysts became larger).

disappeared, leaving behind seven cysts with a maximum diameter of 2 cm (Figure 2B). When no further changes in the liver cysts were observed during the next 2 months of mebendazole therapy, administration was stopped. Shortly after the cessation of mebendazole, the liver cysts enlarged again and the patient underwent surgery in which all of the visible cysts were resected or evacuated and the liver was irrigated by hypertonic saline. Mebendazole was given for another 4 weeks after surgery. No side effects attributable to the mebendazole were observed during treatment.

Due to subsequent recurrence of the liver cysts, the patient had two more surgical operations to remove the larger cysts. Most of the smaller cysts shrank and calcified after operation, then new cysts appeared within a few months. At the time this patient was lost to follow up, she had numerous small cysts in the liver but was apparently in good health.

DISCUSSION

Limited data are available on the epidemiology, clinical characteristics, and optimal therapy of CE in childhood despite the fact that diagnosis has become much easier with advances in modern technology such as ultrasound, computerized tomography, and magnetic resonance. In Turkey, the

incidence of CE has been estimated at 1/2,000 in the general population and nearly one-third of all reported cases from Turkey are under the age of 20 years (6,11). In Greece, only 11% of all cases are children (<18 years of age), probably due to greater rate of urbanization (3).

In a large series of children with CE, the most common anatomic locations were the liver (60-80%), lung (10-30%), or both (10-20%). CE is rarely seen in other organs including the kidney, central nervous system, peritoneum, and bone. Kidney involvement accounts for 4-5% of children with CE and is often accompanied by liver or lung cysts. Simultaneous occurrence in these three organs as we observed in our case has not been previously reported in a childhood series (2,3,7,12,13). In contrast to the usual x-ray appearance of one or more solitary cysts, diffuse involvement of both lung fields by numerous similar-sized cysts was observed in our patient, probably due to dissemination of the embryo from a ruptured liver cyst within the lung parenchyma via pulmonary arterial circulation.

Surgery has been the basic treatment modality of CE for many years despite a significant risk of mortality and high incidence of recurrence particularly of lung cysts (14,15). In recent years, trials with mebendazole or albendazole have given encouraging results, especially in cases of multiple or inoperable cysts. Clinical experience with mebendazole indicates that the drug is most effective and free of side effects when administered at a daily dose of 40-50 mg per kilogram of body weight (16,17). Göçmen et al. reported that mebendazole at a dose of 50 mg/kg cured lung cysts in 20 of 21 children within a median period of 12 months (5). The therapeutic effect was poor at lower doses and shorter treatment duration. Simple solitary cysts in the lung and liver responded better than multiple cysts.

In our patient, mebendazole therapy at a dose of 40 mg/kg per day produced dramatic effect within the first month of treatment. All of the lung cysts, the solitary cyst in the kidney, and most of the smaller cysts in the liver disappeared within 13 months. Therapeutic response in hepatic cysts is usually poor. Although the reason for this is unclear, Richards et al. suggested that high macrophage activity in lung tissue may contribute to the therapeutic process (18).

In conclusion, remarkable treatment outcome in our patient suggests that mebendazole treatment at appropriate doses and duration can be effective in children with disseminated CE, especially for small lung cysts, if there is no urgent indication for surgery. The drug seems to be free of side effects in long term administration. The effectiveness of combination treatment with benzimidazoles and praziquantel remains to be determined in liver CE, which is usually unresponsive to monotherapy.

REFERENCES

1. Sayek, I. (1983): Hydatid disease of the liver. *Hacettepe Med. J.*, 16, 84-92.
2. Nourmand, A. (1976): Hydatid cysts in children and youths. *Am. J. Trop. Med. Hyg.*, 25, 845-847.
3. Matsaniotis, N., Karpathios, T. H., Koutoyzis, J., Nicolaidou, P., Fretzayas, A., Papadellis, F. and Thomardis, T. H. (1983): Hydatid disease in Greek children. *Am. J. Trop. Med. Hyg.*, 32, 1075-1078.
4. Chaouachi, B., Ben Salah, S., Lakhoua, R., Hammou, A., Gharbi, H.A. and Saied, H. (1989): Hydatid cysts in children. Diagnostic and therapeutic aspects. *Apropos of*

- 1195 cases. *Ann. Pediatr.*, 36, 441-449.
5. Göçmen, A., Toppare, M.F. and Kiper, N. (1993): Treatment of hydatid disease in childhood with mebendazole. *Eur. Respir. J.*, 6, 253-257.
 6. Demirbilek, S., Sander, H., Atayurt, F. and Aydın, G. (2001): Hydatid disease of the liver in childhood: the success of medical therapy and surgical alternatives. *Pediatr. Surg. Int.*, 17, 373-377.
 7. Mottaghian, H., Mahmoudi, S. and Vaez-Zadeh, K. (1982): A ten-year survey of hydatid disease (*Echinococcus granulosus*) in children. *Prog. Pediatr. Surg.*, 15, 95-112.
 8. Montessor, A., Awasthi, S. and Crompton, D. W. (2003): Use of benzimidazoles in children younger than 24 months for the treatment of soil-transmitted helminthiasis. *Acta Trop.*, 86, 223-232.
 9. Al-Bassam, A., Hassab, H., al-Olayet, Y., Shadi, M., al-Shami, G., al-Rabeeah, A. and Jawad, A. (1999): Hydatid disease of the liver in children. *Ann. Trop. Paediatr.*, 19, 191-196.
 10. Langer, J. C., Rose, D. B., Keystone, J. S., Taylor, B. R. and Langer, B. (1984): Diagnosis and management of hydatid disease of the liver. *Ann. Surg.*, 199, 412-417.
 11. Şenyüz, O.F., Celayir, A.C., Kılıç, N., Celayir, S., Sarımurat, N., Erdoğan, E. and Yeker, D. (1999): Hydatid disease of the liver in childhood. *Pediatr. Surg. Int.*, 15, 217-220.
 12. Slim, M. S. and Akel, S. R. (1982): Hydatidosis in childhood. *Prog. Pediatr. Surg.*, 15, 119-129.
 13. Zmerli, S., Ayed, M., Horchani, A., Chami, I., El Ouakdi, M. and Ben Slama, M. R. (2001): Hydatid cysts of the kidney: diagnosis and treatment. *World J. Surg.*, 25, 68-74.
 14. Jerray, M., Benzarti, M., Garrouche, A., Klabi, N. and Hayouri, A. (1992): Hydatid disease of the lungs. Study of 386 cases. *Am. Rev. Respir. Dis.*, 146, 185-189.
 15. Çetin, G., Doğan, R., Yüksel, M., Alp, M., Uçanok, K., Kaya, S. and Unlu, M. (1988): Surgical treatment of bilateral hydatid disease of lung via median sternotomy: experience in 60 consecutive patients. *Thorac. Cardiovasc. Surg.*, 36, 114-117.
 16. Vutova, K., Mechkov, G., Vachkov, P., Petkov, R., Georgiev, P., Hangiev, S., Ivanov, A. and Todorov, T. (1999): Effect of mebendazole on human cystic echinococcosis: the role of dosage and treatment duration. *Ann. Trop. Med. Parasitol.* 93, 357-365.
 17. Kayser, H. J. S. (1980): Treatment of hydatid disease with mebendazole at Frere Hospital, East London. *S. Afr. Med. J.*, 58, 560-563.
 18. Richards, K. S., Ilderton, E. and Yardley, H. J. (1987): Lipids in the laminated layer of liver, lung and daughter hydatid cysts of equine *Echinococcus granulosus*. *Comp. Biochem. Physiol.*, 86, 209-221.