

Short Communication

An Unexpected Outbreak of Japanese Encephalitis in the Chugoku District of Japan, 2002

Ryusuke Ayukawa, Hiroshi Fujimoto, Mitsuyoshi Ayabe, Hiroshi Shoji*, Ryukichi Matsui¹,
Yuko Iwata², Hitoshi Fukuda², Kazuhide Ochi³, Koichi Noda³, Yoichi Ono⁴,
Kenichi Sakai⁴, Yasushi Takehisa⁵ and Kotaro Yasui⁶

The First Department (Neurology) of Internal Medicine, Kurume University School of Medicine, Fukuoka 830-0011,

¹Department of Internal Medicine, Tsuwanokyouzon Hospital, Shimane 699-5604,

²Department of Neurology, Masuda Red Cross Hospital, Shimane 698-0003,

³Department of Neurology, Hiroshima National Hospital, Hiroshima 739-0041,

⁴Department of Neurology, National Okayama Medical Center, Okayama 701-1192,

⁵Department of Neurology, Tottori Municipal Hospital, Tottori 680-8501 and

⁶Department of Microbiology, Tokyo Metropolitan Institute for Neurosciences, Tokyo 183-8526, Japan

(Received December 12, 2003. Accepted March 8, 2004)

SUMMARY: Six patients unexpectedly presented with Japanese encephalitis (JE) from early August to mid-September 2002 in the Chugoku district of Japan. The mean age was 67.5 years (range 42-89 years); the onset period in two patients shifted to the middle of September. The JE virus was isolated from the cerebrospinal fluid samples from two patients, and the strain isolated in the one was identified as genotype III. Neurologically, consciousness impairment, meningeal signs, rigidity, hemiparesis, tetraparesis, and convulsive seizures were commonly observed. Magnetic resonance imaging uniformly revealed high signal intensities in the bilateral thalami, brainstem (substantia nigra), hippocampi, and brain cortices. In all patients, acyclovir was used, due to the unexpected outbreak of JE. Five patients, except for one without sequelae, had a severe outcome, including one death. This report indicates that JE in Japan is still a threat to adults and the elderly with decreased or absent immunity to the JE virus.

In recent years, the incidence of Japanese encephalitis (JE) in Japan has decreased to less than several patients per year (1,2). The main reason for this decrease is considered to be the widespread JE virus vaccination of children and the decreased number of pig farms located near cities. However, six patients unexpectedly presented with JE in the Chugoku district (Hiroshima, Shimane, Okayama, and Tottori Prefectures) in the period from early August to mid-September, 2002. The Chugoku area is located in southwestern Japan (Fig. 1) in an area in which JE had not occurred for the past 10 years prior to this outbreak. One of the affected patients was observed during the recovery stage at our University Hospital. We report herein the details regarding this patient who developed JE in Shimane Prefecture. In addition, the clinical characteristics of these six patients are compared with those in patients involved in outbreaks from 1984 to 1993 in the Kurume region of Fukuoka Prefecture, on the island of Kyushu in southern Japan (3-5).

A 42-year-old man with no clear signs of mosquito bites and with no overseas stays had spent some time river-fishing at the beginning of September 2002. He had not received a vaccination for the JE virus for at least the past 10 years. A summary of the course of illness of this patient, who was from Shimane, is shown in Table I (Patient 6). On September 19th, this patient had an acute onset with fever and he was in a confused state. The patient was admitted to a nearby

hospital (the clinical findings observed at the acute stage were reported by Iwata et al. at the 73rd Japanese Chugoku-Shikoku Neurological Congress, unpublished data, 2002). The patient showed altered consciousness with meningeal signs, aphasia, and right hemiparesis. The cerebrospinal fluid (CSF) test revealed a normal pressure of 180 mmH₂O, cell counts of 210 / μ l, protein 272 mg/dl, and glucose 69 mg/dl. Complement fixation (CF) and hemagglutination inhibition (HI)

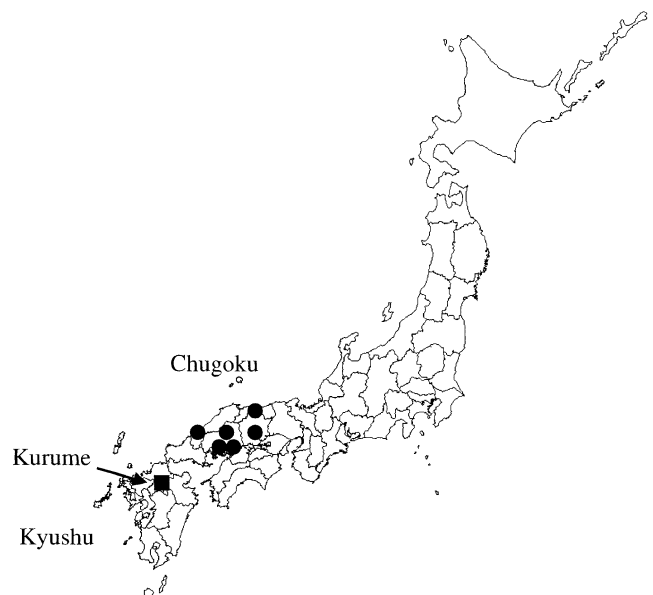


Fig. 1. Six patients presenting with Japanese encephalitis (JE) in the Chugoku district of Japan, 2002 (● = JE patient).

*Corresponding author: Mailing address: The First Department (Neurology) of Internal Medicine, Kurume University School of Medicine, Asahimachi 67, Kurume, Fukuoka 830-0011, Japan. Tel: +81-942-35-3311, Fax: +81-942-31-7703, E-mail: hshoji@med.kurume-u.ac.jp

titers for the JE virus were raised significantly during the acute through the recovery stages; serum CF increased <1:4 to 1:64, and the HI titer was high at 1:2560. However, serum treated with 2-mercaptoethanol (2-ME), indicative of IgM-sensitive antibody, showed no significant changes during that period (1:640). Computed tomography (CT) images of the brain on the fifth day of illness revealed a left-sided, predominant, large low-attenuation in the bilateral thalami, with marked brain edema in the supratentorial regions (Fig. 2A). Two months later, dementia and tetraparesis remained. Electroencephalogram showed a diffuse slow wave, predominantly on the left side. Magnetic resonance imaging (MRI) scans of the brain demonstrated high signal intensities in the bilateral thalami, basal ganglia, hippocampi, brain cortices, and brainstem, including the substantia nigra, with moderate dilatation of the ventricular system (Figs. 2B, 2C). Six months after the onset of the disease, the patient was transferred to our University Hospital for neurological evaluation. He was alert, but had no verbal response, and he followed family members or hospital workers with his eyes. Stereotypical behavior was observed; for example, after he was given a children's magazine, he repeatedly paged through it. The

sucking reflex and snout reflex were positive. Tetraparesis was observed predominantly on the right side, while hyperreflexia and a positive Babinski reflex were observed bilaterally with flexion of the lower limbs. Severe dementia and tetraparesis remained as sequelae, and the patient was transferred to another hospital for rehabilitation.

During the same period, five patients with JE were identified in the Chugoku district (Hiroshima, Okayama, and Tottori Prefectures); data for these patients were presented at the 73rd Japanese Chugoku·Shikoku Neurological Congress, December 2002 (Patients 1-3, Hiroshima; Ochi et al., Patient 4, Okayama; Ono et al., and Patient 5, Tottori; Takehisa et al., unpublished data, 2002). The clinical characteristics and results of the virologic studies, including those of our present patient (Patient 6, Shimane), are shown in Table 1. The mean age of these patients was 67.5 years (range: 42-89 years); the male-to-female ratio was 1:1, and the onset period extended from the beginning of August to mid-September, 2002. Neurological symptoms at the acute stage consisted of consciousness impairment, meningeal signs, hemiparesis, tetraparesis, convulsive seizures, and muscular rigidity. As with Patient 6, Patient 5 had spent time at a nearby river

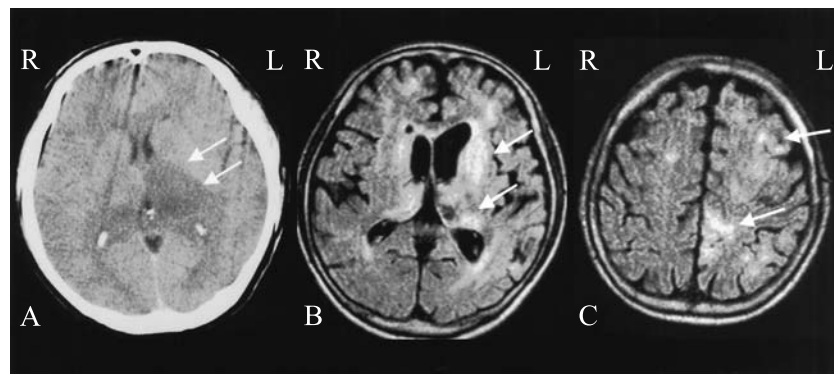


Fig. 2. CT and MRIs of Patient 6 with Japanese encephalitis.

A: Five days after onset, an axial plain CT demonstrating bilateral thalamic lesions, with severe brain edema (arrows shows only the left side). B: Two months after onset, axial FLAIR MRI revealing widespread high signals bilaterally in the thalami and basal ganglia (arrows) and C: High-intensity lesions in the left frontal and parietal cortices (arrows).

Table 1. Clinical characteristics and virologic studies in six patients with Japanese encephalitis

Patient no.	Age/Sex (yrs) Place	Onset date	Clinical fever	symptoms impaired consciousness	Serum antibody titers for JEV			virus isolate from CSF	MRI lesions	Outcome	
					illness days	HI (2-ME)	CF				ELISA IgM
1	89/F Hiroshima	5 Aug	(+) (+)	Me, tetraparesis	10	160 (80)		+	+	Th, S, H, WM	(++)
					32	320 (160)					
2	77/F Hiroshima	29 Aug	(+) (+)	Me, tetraparesis	5	20 (10)		+		Th, H	dead
					15	2560 (1280)					
3	60/M Hiroshima	23 Aug	(+) (+)		4		16	+	+	n.d.	(-)
					18	1280	128				
4	58/F Okayama	5 Sep	(+) (+)	Me, seizures	6	160 (20)	<4			Th, H	(++)
					13	640 (640)	16				
5	77/M Tottori	15 Sep	(+) (+)	Me, rt rigidity lt hemiparesis	16	640	<4			Th, S	(++)
					23	2560 (80)					
6	42/M Shimane	19 Sep	(+) (+)	Me, aphasia rt hemiparesis	8		<4			Th, H, S, C	(++)
					22		32				
					38	2560 (640)	64				

M: male, F: female, Yrs: years, Me: meningeal signs, rt: right, lt: left, JEV: Japanese encephalitis virus, HI: hemagglutination inhibition, 2-ME: 2-mercaptoethanol, CF: complement fixation, ELISA: captured enzyme immunosorbent assay, CSF: cerebrospinal fluid, MRI: magnetic resonance imaging, Th: thalamus, S: substantia nigra, H: hippocampus, WM: white matter, C: cortex, n.d.: not done, outcome: (-)=no sequelae, (++)=severe sequelae, st.: stereotypical behavior.

before the onset of the disease. In Patient 4, involuntary movements similar to ballism were temporally observed following the acute stage. Dementia, hemiparesis, tetraparesis, parkinsonism, and involuntary movements are generally observed as the sequelae of JE (3,6,7). In Patients 1 and 4-6 in the present outbreak, dementia, stereotypical behavior, parkinsonism, and tetraparesis with pathological reflexes remained after recovery.

Five patients (Patients 1, 2, and 4-6) had not received the JE virus vaccination for at least the past 10 years, and remained uncertain whether or not the remaining patient, Patient 3, had been vaccinated. In all patients, a significant increase in antibody titers was observed by HI or CF testing, and in Patients 1-3, captured enzyme immunoassay (ELISA) IgM antibody was detected. The CSF of these cases revealed moderate pleocytosis, and an increase in protein content. The JE virus was isolated from the CSF samples from Patients 1 and 3, and the strain isolated in Patient 1 was identified as genotype III (2,8). MRI was carried out in five patients, i.e., excluding Patient 2. Lesions were found by MRI in the bilateral thalami, midbrain (substantia nigra), hippocampi, white matter, and brain cortices. In Patients 5 and 6, severe brain edema in the supratentorial areas was observed. In all patients, acyclovir with or without corticosteroids was administered. Patient 3 was discharged without particular sequelae, but the other five patients had severe outcomes, and one patient died.

When the case histories of these six patients are compared with those of patients in previous outbreaks of JE, which occurred around 1990 in the Kurume region on Kyushu island, the following can be noted. First, the time of onset in two patients was mid-September, whereas in previous outbreaks, most onset times were in August (3-5). One patient with JE in the Hokuriku district (Ishikawa Prefecture) in the same year, 2002, had an onset in the middle of October (2). In 2003, we encountered a new patient with JE in the Kurume region; onset occurred in this patient at the end of September (unpublished data, 2003). Preliminary rapid data regarding JE virus antibody acquisition in swine throughout Japan are reported every summer on a weekly basis (National Epidemiological Surveillance of Vaccine-Preventable Diseases [in Japanese]; the full text is available on the Web site, 2002, at <http://idsc.nih.go.jp/yosoku/99/2002JE/JJE2-6.htm>); the dates at which a more than 50% positivity occurred in 2002 were July 29th at Hiroshima, September 3rd at Shimane, and July 16th at Fukuoka. The peak of seroconversion in pigs has been delayed, compared to that in the 1960s (1,2), although there are time differences from year to year. The delayed onset of JE during the middle of September to October may have correlated with delayed seropositivity to the JE virus in swine. In addition, JE should be considered as a possible differential diagnosis, even when unknown viral encephalitis occurs from the middle of September to October.

Regarding mortality and morbidity, in the previous outbreaks in the Kurume region from 1984-1990 and 1991-1993, the former outbreak (4) had a high mortality rate (4 of 10 patients), while in the latter outbreak (5), the mortality was low (none of 4 patients); in contrast, in the present outbreak, five patients had severe outcomes, including one death. In terms of the neurological findings, in the previous outbreaks in the Kurume region from 1984-1990, a high incidence of white matter involvement was found on MRI, while in the present outbreak, stereotypical behavior with severe dementia was observed in two patients. These year-dependent differences,

including the neurological findings, might be reflective of variation in the viruses or the host conditions. As regards the neurogenicity of the JE virus, Yasui et al. (9,10) have identified a genome responsible for neuropathogenesis located on the E-protein-coding region, and have reported that this region is stable over a long period of time. In recent years, it has been demonstrated that both genotypes I and III exist in Japan, and genotype I has tended to increase (11). In reference to genotype III, identified in Patient 1, Kuwayama et al. (2,8) briefly noted that the E-protein-coding region was almost identical to that of the classical JaGAR strain. We therefore speculate that the severity of JE may depend on the host conditions, rather than on changes in the neurogenicity of the JE virus. However, further studies are needed to elucidate this link, because only a limited number of strains have been isolated from the CSF in JE patients.

In Japan, JE virus vaccination for adults and the elderly has not been considered practical due to the very low incidence of JE. The cycle of transmission to humans of the JE virus consists of mosquitoes to amplifying host-swine, and then again infection from mosquitoes to humans. A high seropositive ratio of pigs for the JE virus persists, particularly in western areas of Japan (1,2). JE virus vaccination may be recommended for the elderly with low immunity in the western areas of Japan. Meanwhile, in the present outbreak, acyclovir was administered due to the unexpected appearance of JE patients. Interferon- α , ribavirin, and 6-azauridine have proven to have in vitro efficacy against pathogenic flaviviruses (12,13). Hereafter, the use of these drugs should be attempted for treating suspected JE patients instead of acyclovir.

Finally, in our Patient 6, fluid-attenuated inversion recovery (FLAIR) MRI more clearly demonstrated cortical lesions caused by JE. MRI lesions in the thalami, basal ganglia, brainstem (substantia nigra), and brain cortices have accumulated in Japanese and Indian patients with JE (3,4,14-17). The bilateral thalamic and brainstem lesions seen on CT and MRI are highly indicative of JE. In addition, these changes are also observed in flavivirus encephalitis such as Russian Spring-Summer encephalitis, Murrey Valley encephalitis, West Nile encephalitis, and St. Louis encephalitis (18-22).

ACKNOWLEDGMENTS

We would like to thank Dr. Yasuhiro Manabe, Department of Neurology, National Okayama Medical Center, for providing valuable information about Patient 4.

REFERENCES

1. Matsunaga, Y., Yabe, S., Taniguchi, K., Nakayama, M. and Kurane, I. (2000): Current status of Japanese encephalitis in Japan. *J. Jpn. Assoc. Infect. Dis.*, 73, 97-103 (in Japanese).
2. National Institute of Infectious Diseases and Tuberculosis and Infectious Diseases Control Division, Ministry of Health, Labour and Welfare (2003): Japanese encephalitis, Japan, 1999-2002. *Infect. Agents Surveillance Rep.*, 24, 149'-150'.
3. Shoji, H., Hiraki, Y., Kuwasaki, N., Toyomasu, T., Kaji, M. and Okudera, T. (1989): Japanese encephalitis in the Kurume region of Japan. *J. Neurol.*, 236, 255-259.
4. Shoji, H., Kida, H., Hino, H., Matsuura, S., Kojima, K., Abe, T., Utsunomia, H., Okada, Y., Nakamura, Y. and

- Okudera, T. (1994): Magnetic resonance imaging findings in Japanese encephalitis: white matter lesions. *J. Neuroimaging*, 4, 206-211.
5. Shoji, H., Azuma, K., Nishimura, Y., Fujimoto, H., Sugita, Y. and Eizuru, Y. (2002): Acute viral encephalitis: The recent progress. *Intern. Med.*, 41, 420-428.
 6. Pradhan, S., Pandey, N., Shashank, S., Gupta, R. K. and Mathur, A. (1999): Parkinsonism due to predominant involvement of substantia nigra in Japanese encephalitis. *Neurology*, 53, 1781-1786.
 7. Tabata, K., Hattori, T. and Matsuda, M. (2000): Japanese encephalitis presenting with left hemiplegia and thalamic neglect. A case report. *Rinsho Shinkeigaku*, 40, 929-932 (in Japanese).
 8. Kuwayama, M., Takao, S., Fukuda, S., Shimazu, S., Miyazaki, I., Kurane, I., Takasaki, T., Yamada, K., Nerome, R., Ito, M., Kasamatsu, J., Nakamura, S., Miyawaki, H., Kagawa, H., Aoyama, N., Ochi, K., Harada, W. and Tokinobu, H. (2003): Three cases of Japanese encephalitis occurring in the Hiroshima Prefecture, 2002. *Infect. Agents Surveillance Rep.*, 24, 63-64 (in Japanese).
 9. Kimura-Kuroda, J. and Yasui, K. (1986): Antigenic comparison of envelope protein E between Japanese encephalitis virus and some other flaviviruses using monoclonal antibodies. *J. Gen. Virol.*, 67, 2663-2672.
 10. Yasui, K. (2002): Neuropathogenesis of Japanese encephalitis virus. *J. Neurovirology*, 8 (Suppl. 2), 112-114.
 11. Takegami, T. (2002): Topics on isolation of Japanese encephalitis virus. *Infect. Agents Surveillance Rep.*, 24, 153-155 (in Japanese).
 12. Crance, J. M., Scaramozzino, N., Jouan, A. and Garin, D. (2003): Interferon, ribavirin, 6-azauridine and glycyrrhizin; antiviral compounds active against pathogenic flaviviruses. *Antiviral Res.*, 58, 73-79.
 13. Solomon, T., Dung, N. M., Wills, B., Kneen, R., Gainsborough, M., Diet, T. V., Thuy, T. T. N., Loan, H. T., Khanh, V. C., Vaughn, D. W., White, N. J. and Farrar, J. J. (2003): Interferon alfa-2a in Japanese encephalitis: a randomised double-blind placebo-controlled trial. *Lancet*, 361, 821-826.
 14. Shoji, H., Murakami, T., Murai, I., Kida, H., Sato, Y., Kojima, K., Abe, T. and Okudera, T. (1990): A follow-up study by CT and MRI in 3 cases of Japanese encephalitis. *Neuroradiology*, 32, 215-219.
 15. Abe, T., Kojima, K., Shoji, H., Tanaka, N., Fujimoto, K., Uchida, M., Nishimura, H., Hayabuchi, N. and Norbash, A. M. (1998): Japanese encephalitis. *J. Magn. Reson. Imaging*, 8, 755-761.
 16. Misra, U. K., Kalita, J., Jain, S. K. and Mathur, A. (1994): Radiological and neurophysiological changes in Japanese encephalitis. *J. Neurol. Neurosurg. Psychiatry*, 57, 1484-1487.
 17. Kalita, J. and Misra, U. K. (2000): Comparison of CT scan and MRI findings in the diagnosis of Japanese encephalitis. *J. Neurol. Sci.*, 174, 3-8.
 18. Lorenzl, S., Pfister, H. W., Padovan, C. and Yousry, T. (1996): MRI abnormalities in tick-borne encephalitis. *Lancet*, 347, 698-699.
 19. Takezawa, C., Sato, T., Mizutani, Y., Abe, S. and Morita, K. (1995): Russian spring-summer encephalitis. A case report. *Shinkeinaika*, 43, 251-255 (in Japanese).
 20. Cerna, F., Mehrad, B., Luby, J. P., Burns, D. and Fleckenstein, J. L. (1999): St. Louis encephalitis and the substantia nigra: MR evaluation. *Am. J. Neuroradiol.*, 20, 1281-1283.
 21. Rosas, H. and Wippold II, F. J. (2003): West Nile virus: Case report with MR imaging findings. *Am. J. Neuroradiol.*, 24, 1376-1378.
 22. Einsiedel, L., Kat, E., Ravindran, J., Slavotinek, J. and Gordon, D. L. (2003): MR findings in Murray Valley encephalitis. *Am. J. Neuroradiol.*, 24, 1379-1382.