

## Laboratory and Epidemiology Communications

### First Case of Cerebral Phaeohyphomycosis Caused by *Natrassia mangiferae* in Iran

Mohsen Geramishoar, Kamiar Zomorodian, Farideh Zaini, Farshid Saadat<sup>1</sup>,  
Bita Tarazooie, Mehdi Norouzi<sup>1</sup> and Sassan Rezaie\*

Division of Molecular Mycology, Department of Medical Mycology & Parasitology and  
<sup>1</sup>Department of Immunology, School of Public Health and Institute of Public Health Research,  
Tehran University of Medical Sciences, Tehran, Iran

Communicated by Yoshimasa Uehara

(Received June 28, 2004. Accepted October 12, 2004)

Phaeohyphomycosis is a cosmopolitan infection that is caused by a number of phaeoid fungi. They are characterized by development of dark colored filamentous hyphae in the involved tissues. Phaeohyphomycosis includes a wide spectrum of infections that vary from superficial colonization of the skin or cornea to cutaneous, subcutaneous, cerebral and systemic infections. Cerebral phaeohyphomycosis is rare but is the most serious form of this infection (1). Various fungi have been described as agents of cerebral phaeohyphomycosis. Herein we isolated *Natrassia mangiferae* from cerebral abscess as the etiological agent of cerebritis.

The coelomycete *N. mangiferae* (synanamorph *Scytalidium dimidiatum*) is a filamentous fungus, which was first described in 1916 as *Dothiorella mangiferae* (2). Until recently, it was classified as *Hendersonula toruloidea* Natrass (3,4). In the latest revision of the genus *Hendersonula*, it was reclassified in its own genus based on its pycnidial stage (5). In addition, the *Scytalidium* synanamorph was proposed for its arthroconidial stage (6). Three morphological variants were identified within this genus, including a fast, a slow, and an intermediate growing type (3). Because pycnidia may be difficult to detect or may be absent, as is the case in slow-growing isolates, *N. mangiferae* may sometimes be misdiagnosed as *Scytalidium lignicola*. However these two species can be differentiated by other morphological characteristics (7).

The patient was a 17-year-old male with a history of systemic lupus erythematosus (SLE), which was indicated by renal involvement. Four months before hospitalization, he was treated by prednisolone (75 mg/d) and cyclophosphamide (pulse therapy) for knee and ankle arthralgia. He was hospitalized in the Neurology Department because of seizure, fever, neck rigidity, drowsiness and Kernig's sign. He received broad-spectrum antibiotics under suspicion of septic meningitis. His lumbar puncture examination revealed increased CSF pressure and cloudy appearance. A hypodense area in the frontal lobe on the right side was seen on his CT brain scan. After craniotomy and drainage of abscess, a sample was examined in the Mycology Department of the Tehran

University of Medical Sciences.

The examination of histological sections staining with PAS and H&E as well as wet mount (KOH 10%) preparation of sample indicated branched dematiaceous and non-pigmented hyphae (Fig. 1, 2). In addition, several conidia were also observed concomitant with PAS-positive hyphae. The specimen was cultured on brain heart infusion agar (BHIA), Sabouraud dextrose agar (S), and Sabouraud's containing 0.005% chloramphenicol (Sc). The S and Sc culture media were incubated at 25°C and BHIA at 37°C. The colonies grew rapidly, attaining a diameter of 7.5-9 cm within a week. Their color was primarily white to bluish-green, which gradually became dark olivaceous to black with age and finally overlaid the petri dish with aerial greyish black mycelia. The reverse of colonies was initially ecru but slowly darkened to ashen black.

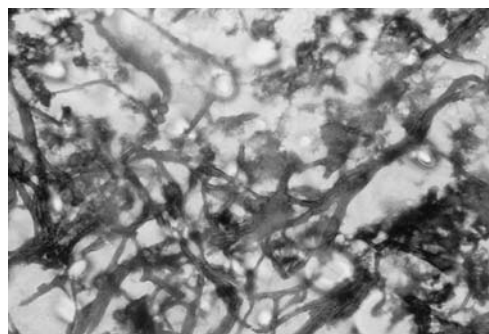


Fig. 1. PAS-positive fungal elements observed in histological section of brain abscess (magnification  $\times 100$ ).

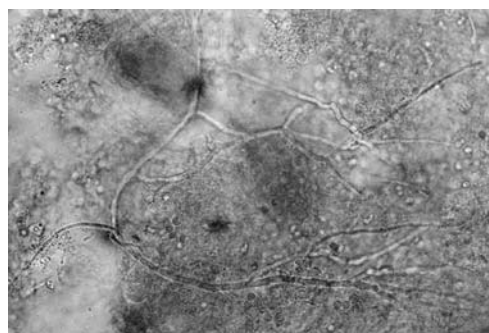


Fig. 2. KOH 10% preparation of specimen showing branched septated subhyaline hyphae (magnification  $\times 100$ ).

\*Corresponding author: Mailing address: Division of Molecular Mycology, Department of Medical Mycology & Parasitology, School of Public Health and Institute of Public Health Research, Tehran University of Medical Sciences, P.O. Box: 14155-6446, Tehran, Iran. Tel: +98-21-8951583, Fax: +98-21-6462267, E-mail: srezaie@sina.tums.ac.ir

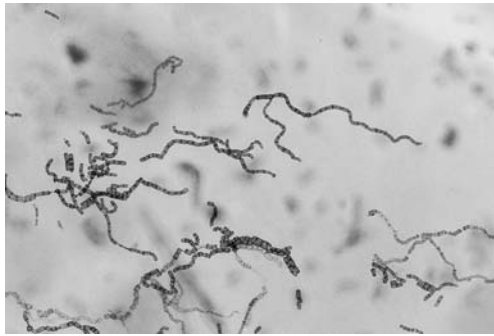


Fig. 3. Slide culture preparation demonstrates chains of non-septated or one-septated barrel-shaped arthroconidia arranged in a zigzag form.

Slide cultures of these colonies demonstrated narrow-branching and wide subhyaline to dark brown hyphae which fragmented to one-septate or no-septate arthroconidia. Chains of thick-walled, cylindrical arthroconidia arranged in a zigzag form were observed in cellophane tape preparations (Fig. 3). Because many pathogenic or saprophytic fungi can also produce arthroconidia in culture, differentiation between *N. mangiferae* and arthroconidial fungi should be considered. Mushrooms and shelf fungi such as *Bjerkandera adusta*, which is common contaminant of clinical samples, can produce arthroconidia in culture, but these are urease-positive (4). *Geotrichum* spp. can also be differentiated by their purely white colonies and rectangular arthroconidia which germinate at one end, giving the appearance of a bud. Moreover, *Trichosporon* spp. can be distinguished by yeast-like colonies as well as budding cells in addition to abundant barrel-shaped and ellipsoidal arthroconidia (4). *Coccidioides* spp. differ by having thick-walled arthroconidia, alternating with thin-walled empty cells (disjunctors).

Based on these histological and mycological findings, *N. mangiferae* was determined as the causative agent of cerebral phaeohyphomycosis in this case. Although the patient had received amphotericin B incrementally at a final dosage of 300 mg/d, he did not respond to the treatment and died within a week after initial antifungal therapy.

The term phaeohyphomycosis was first proposed in 1974 by Ajello et al. (8) to describe cutaneous, subcutaneous, and systemic infections caused by hyphomycetous fungi that develop as dematiaceous septate hyphae in host tissue. Since then, many pigmented fungi have been identified, and the term phaeohyphomycosis has come to include all members of hyphomycetes, coelomycetes, and ascomycetes that appear dematiaceous in tissue (9).

The majority of cases of cerebral phaeohyphomycosis are usually due to neurotropic fungi such as *Cladophialophora bantiana*. In the present case, histological and mycological findings revealed that *N. mangiferae* was the causative agent of cerebral phaeohyphomycosis.

*N. mangiferae* is known as a wound-invading pathogen of a variety of woody hosts in tropical and subtropical countries. Although human skin and nail infections due to this fungus are well documented, invasive infections are rare (10). Reports have included facial lesions, mycetoma, subcutaneous abscesses, fungemia, and endophthalmitis (4,7). Our review of the literature revealed no prior case of cerebral phaeohyphomycosis due to this fungus.

Immunosuppression is typically the underlying condition that predisposes a patient to deep opportunistic infections. As previously mentioned, SLE has been associated with other

superficial and systemic fungal infections (4,11). Our patient was predisposed to *N. mangiferae* infection due to SLE and therapy with high dose corticosteroid and cyclophosphamide.

The only case of phaeohyphomycosis observed previously in Iran was reported by Rasoolinejad et al. (12) from subcutaneous nodes and nasopharyngeal lesions. Therefore, the present case appears to be the first case of cerebral phaeohyphomycosis in Iran. Although this fungus is very common in the environment, its poor invasive capacity, and the failure of identification and isolation in routine fungal culture media containing cycloheximide could be assumed as factors involved in its low incidence in deep infection. Thus, *N. mangiferae* infection should be considered as a possible additional factor of morbidity in immunocompromised patients.

## REFERENCES

1. Osiyemi, O. O., Dowby, L. M., Mallon, S. M. and Cleary, T. (2001): Cerebral hyphomycosis due to a novel species: report of a case and review of the literature. *Transplantation*, 71, 1343-1346.
2. Lacaz, C.S., Pereira, A.D., Heins-Vaccari, E.M., Cuce, L.C., Benatti, C., Nunes, R.S., de Melo, N.T., de Freitas-Leite, R.S. and Hernandez-Arriagada, G. L. (1999): Onychomycosis caused by *Scytalidium dimidiatum*. Report of two cases. Review of the taxonomy of the synanamorph and anamorph forms of this coelomycete. *Rev. Inst. Med. Trop. Sao Paulo*, 41, 319-323.
3. Moore, M. K. (1988): Morphological and physiological studies of isolates of *Hendersonula toruloidea* Nattrass cultured from human skin and nail samples. *J. Med. Vet. Mycol.*, 26, 25-39.
4. De Hoog, G. S., Guarro, J. and Figueras, M. J. (2000): *Atlas of Clinical Fungi*. p. 329-331. 2nd ed. Centraalbureau voor Schimmelcultures/Universitat Rovira i Virgili, the Netherlands.
5. Sutton, B. C. and Dyko, B. J. (1989): Revision of *Hendersonula*. *Mycol. Res.*, 93, 466-488.
6. Sigler, L. and Carmichael, J. W. (1976): Taxonomy of *Malbranchea* and some other hyphomycetes with arthroconidia. *Mycotaxon*, 4, 349-488.
7. Sigler, L., Summerbell, R. C., Poole, L., Wieden, M., Sutton, D. A., Rinaldi, M. G., Aguirre, M., Estes, G. W. and Gagliani, J. N. (1997): Invasive *Nattrassia mangiferae* infections: Case report, literature review, and therapeutic and taxonomic appraisal. *J. Clin. Microbiol.*, 35, 433-440.
8. Ajello, L., George, L. K., Steigbigel, R. T. and Wang, C. J. (1974): A case of phaeohyphomycosis caused by new species of *Phialophora*. *Mycologia*, 66, 490-498.
9. Kwon-Chung, K. J. and Bennett, J. E. (1992): *Medical Mycology*. Lea & Febiger, Philadelphia.
10. Moore, M. K. (1992): The infection of human skin and nail by *Scytalidium* species. p. 1-42. In Borgers, M., Hay, R. and Rinaldi, M.G. (eds.), *Current Topics in Medical Mycology*. vol. 4. Springer-Verlag, New York.
11. Sieving, R. R., Kauffman, C. A. and Watanakunakorn, C. (1975): Deep fungal infection in systemic lupus erythematosus - three cases reported, literature reviewed. *J. Rheumatol.*, 2, 61-72.
12. Rasoolinejad, M., Haji-Abolbaghi, M., Emami, M., Zarchi, M. and Geramishoar, M. (1999): Phaeohyphomycosis: cutaneous, subcutaneous, nasopharyngeal lesions. *Acta Med. Iranica*, 37, 30-33.