

Original Article

Combination Therapy of Once-Weekly Fluconazole (100, 150, or 300 mg) with Topical Application of Ketoconazole Cream in the Treatment of Onychomycosis

Xuejun Chen, Masataro Hiruma*, Yumi Shiraki and Hideoki Ogawa

Department of Dermatology, Juntendo University School of Medicine, Tokyo 113-8421, Japan

(Received June 16, 2004. Accepted July 28, 2004)

SUMMARY: In order to assess the safety and efficacy of once-weekly fluconazole orally (100, 150, or 300 mg) with once-a-day topical application of 1% ketoconazole cream in the treatment of onychomycosis in Japan, 121 patients were assigned to one of three fluconazole dosages (100, 150, or 300 mg) and took fluconazole orally, once weekly, for 12 months or until a complete cure was achieved. In addition, once-a-day topical ketoconazole cream was applied. At each weekly visit, adverse events were investigated and the length of the diseased nails was measured. Treatment efficacy was assessed 12 months after discontinuation of fluconazole using the following scale: cured, markedly improved, improved, slightly improved, no change. Mycological cure was assessed using KOH wet mount and fungus culture. The results showed that the numbers of patients achieving marked improvement or better were 38/68 (55%), 13/22 (60%), and 21/31 (67%) for the 100 mg, 150 mg, and 300 mg groups, respectively. There was no significant difference between any two groups. The duration of fluconazole therapy was the longest for patients in the 100 mg group. None of the patients reported adverse effects. These findings led to the conclusion that once-weekly fluconazole with once-a-day application of topical ketoconazole cream appears safe and effective for treating onychomycosis. The dosage of 150 mg once weekly for 6 months was recommended, considering both effectiveness and economy.

INTRODUCTION

Onychomycosis, a common fungal disease with a worldwide incidence reported in recent years to be between 2 and 14% (1,2), affects the quality of life of afflicted patients (3). Before the emergence of a new generation of antimycotics, onychomycosis was one of the most difficult dermatologic diseases to treat. New regimens of these antimycotics using intermittent therapy, pulse therapy, or short-duration therapy have been devised, allowing greater convenience for patients and likely improving their compliance.

Fluconazole is a new-generation antifungal drug belonging to the tri-azole group of antimycotics. The antifungal spectrum of fluconazole overlaps almost all the common strains of fungi responsible for onychomycosis, including *Trichophyton*, *Microsporum*, and *Epidermophyton* (4). Fluconazole also strongly inhibits some uncommon fungi involved in onychomycosis, such as *Candida albicans* (5), and has a superior pharmacokinetic profile (6).

Although intermittent pulse therapy with fluconazole to treat onychomycosis, first proposed by Montero-Gei et al. (7), is widely used in Western countries, this dosing regimen has not been approved in Japan. The aim of this study is to elucidate the safety and effectiveness of an oral intermittent regimen of fluconazole in combination with topical 1% ketoconazole cream for treatment of onychomycosis in Japanese patients.

MATERIALS AND METHODS

Study design: The study population consisted of patients seeking treatment for onychomycosis in the outpatient clinic of the Dermatology Department at Juntendo University School of Medicine from January 1997 to December 2001. Patients were eligible to participate if they had a diagnosis of onychomycosis based on clinical manifestations and confirmed by positive results with both KOH wet-mount and mycological culture. Exclusion criteria were as follows: (i) use of systemic antimycotics within the previous 6 months; (ii) pregnancy or lactation; (iii) allergy to azoles; (iv) previous history of discontinuation of therapy with azoles due to adverse effects; (v) serious systemic diseases; (vi) judgment by the investigator that the patient would be inappropriate for inclusion in this study. All patients provided written informed consent before enrollment.

At each weekly study visit, patients were asked about the occurrence of any adverse events since the previous visit. Adverse events were recorded and appropriate action was taken as needed. Therapy was discontinued 12 months after treatment initiation or upon attaining a clinical cure, defined as complete regrowth of a healthy nail that fully covered the nail plate, and/or a mycological cure determined by negative microscopy.

The following data were collected for each patient: age, gender, and occupation (classified into two groups: blue-collar workers, who were engaged in work that usually created a strain on toenails or fingernails, and white-collar workers); disease duration; lesion site(s) (fingernail or toenail) and number of affected nails (excluding the fifth toenail); severity of nail thickening; clinical type of onychomycosis (distal lateral subungual onychomycosis [DLSO], proximal subungual onychomycosis [PSO], superficial white

*Corresponding author: Mailing address: Department of Dermatology, Juntendo University School of Medicine, 2-1-1 Hongo, Bunkyo-ku, Tokyo 113-8421, Japan. Fax: +81-3-3813-9443, E-mail: mhiruma@med.juntendo.ac.jp

onychomycosis [SWO], or total dystrophic onychomycosis [TDO]); and presence or absence of underlying concomitant diseases.

Patients were divided into three groups to receive once-weekly treatment with fluconazole at 100 mg, 150 mg, or 300 mg orally. Patients continued treatment, with weekly visit to the clinic for a maximum of 12 months, until onychomycosis was cured. Since the fifth month, patients receiving 300 mg fluconazole started to taper the dose to 150 mg until the end of the 12th month or until the onychomycosis was cured. All patients continued to apply 1% ketoconazole cream daily to the area surrounding the nails, interdigital position, or planta pedis, of the affected site and discontinued this local treatment at the follow-up visit at the end of 12th month.

Evaluation of efficacy: The length of diseased nail was measured at every visit. The efficacy criteria were defined by the following five clinical categories: (i) cured: the nail plate was completely covered by healthy new nail; (ii) markedly improved: healthy new nail covered over 70% of the affected nail plate; (iii) improved: healthy new nail covered 40-70% of the affected nail plate; (iv) slightly improved: healthy new nail covered no more than 40% of the affected nail plate; and (v) no change: no change, worsened condition, or treatment discontinued due to adverse effects. Mycological cure was defined as having negative results on KOH wet mount and on fungus culture after treatment.

Statistical analysis: The clinical response was analyzed by means of the Kruskal-Wallis test. Pair-wise comparisons were made by means of the Fisher exact test. All comparisons were made at the 0.05 level of significance.

RESULTS

Patient demographics: One hundred and forty-nine patients with onychomycosis were enrolled in the study. Details on patient disposition are shown in Fig. 1. The study population analyzed for efficacy consisted of a total of 121 patients, 68 patients in the 100 mg group, 22 patients in the 150 mg group, and 31 patients in the 300 mg group.

Patients ranged in age from 20 to 90 years old (mean age 47 ± 18 years). There were no significant differences between patients in the 100 mg and 150 mg groups in terms of patient demographics or clinical history. Patients in the 300 mg group were significantly older (mean age 65 ± 13 years) than patients in the 100 mg group (mean age 48 ± 13 years; $P < 0.001$) and those in the 150 mg group (mean age 46 ± 12 years; $P < 0.001$). In addition, the mean thickness of the

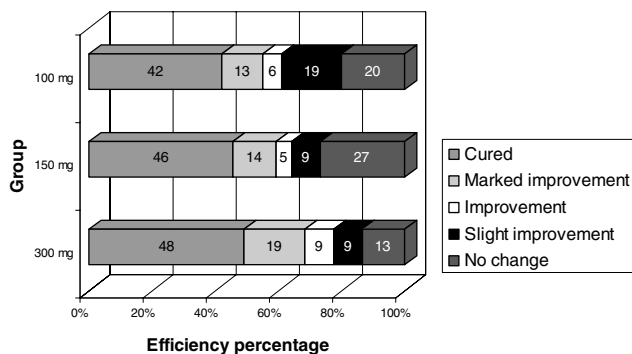


Fig. 1. Efficacy of onychomycosis treated by fluconazole once weekly. The cure rates among the three groups were not statistically different by means of the Kruskal-Wallis test ($P > 0.05$).

Table 1. Patients' background

Group		100 mg	150 mg	300 mg
Cases		68	22	31
Sex	male	35	8	13
	female	33	14	18
Age (yr)		48 ± 13	46 ± 12	65 ± 13
Occupation	blue-collar	8	5	18
	white-collar	23	17	50
Underlying diseases				
without		59	19	11
with		9	3	20
Duration (yr)		7 ± 5	7 ± 5	9 ± 9
Location	finger	5	3	2
	toe	63	19	29
Thickness of diseased nails (mm)		1.4 ± 0.7	1.1 ± 0.8	1.8 ± 0.9
Number of diseased nails		3.3 ± 2.4	3.5 ± 2.2	3.6 ± 2.1
Type of the disease (cases)				
DLSO		66	18	30
SWO		2	2	1
PSO		0	0	0

DLSO, distal lateral subungual onychomycosis; SWO, superficial white onychomycosis; PSO, proximal subungual onychomycosis.

Table 2. Onychomycosis treatment detail

Group	100 mg	150 mg	300 mg
Treatment duration (mo)	8.4 ± 5.6	6.4 ± 3.3	5.6 ± 3.8
Times of administration	33.3 ± 20.0	25.7 ± 12.2	25.6 ± 16.6
Total dosage (mg)	$3,328 \pm 1,989$	$3,859 \pm 1,831$	$6,361 \pm 3,335$

diseased nails in the 300 mg group was 1.8 ± 0.9 mm, which was significantly greater than the mean nail thickness in the 100 mg group (1.4 ± 0.7 mm, $P = 0.009$), but not than that in the 150 mg group (1.1 ± 0.8 mm; $P = 0.14$). Finally, the 300 mg group differed from the other two groups in having a higher number of patients (20 cases) with underlying concomitant disease (Table 1).

Efficacy: *Trichophyton rubrum* was identified as the causative pathogen in all but eight cases, in which *Trichophyton mentagrophytes* was the pathogen. Most of the patients showed marked improvement or better (Fig. 2-3). There were no significant differences among the three groups in clinical cure rate (42, 46, and 48% in the 100 mg, 150 mg, and 300 mg groups, respectively; see Fig. 1) or in the rate of marked improvement and better (55, 60, and 67% for the 100 mg, 150 mg, and 300 mg groups, respectively).

The groups differed significantly in treatment duration and total fluconazole dosage. In the 100 mg group, the average treatment duration (8.4 ± 5.6 months) was significantly longer than the average treatment duration in either of the other two groups (6.4 ± 3.4 months, $P = 0.02$ in the 150 mg group and 5.6 ± 3.8 months, $P = 0.01$ in the 300 mg group). The total fluconazole dosage of $6,361 \pm 3,335$ mg in the 300 mg group was almost double that of either of the other two groups ($3,328 \pm 1,989$ mg in the 100 mg group and $3,859 \pm 1,831$ mg in the 150 mg group, respectively) (Table 2).

None of the patients in any of the three groups experienced treatment-related adverse effects.

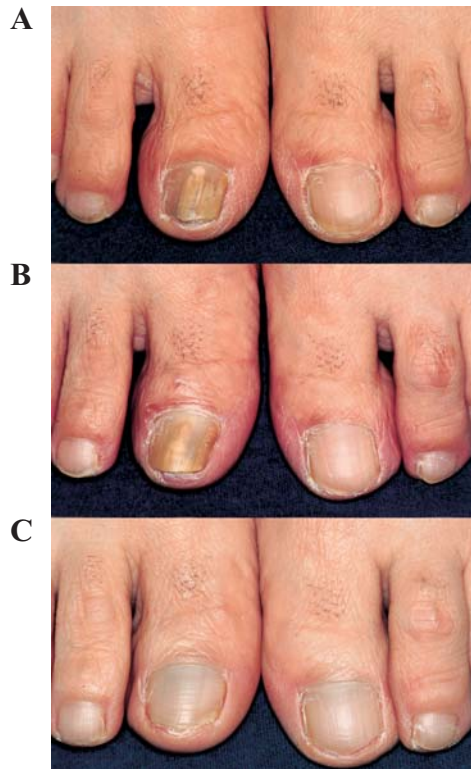

Fig. 2A. A 59-year-old female with toe-nail onychomycosis induced by *T. rubrum*.
 2B. After being treated with fluconazole 300 mg/week for 3 months (16 times of administration in all), the turbidity at the toe-nail center became a line.
 2C. After being treated for 8 months (40 times of administration with total dose of 9,600 mg) and discontinued administration for 4 months, the toe-nail onychomycosis cured.

DISCUSSION

Onychomycosis has traditionally been a difficult infection to treat. Before the emergence of the new generation of antifungal agents, only limited therapeutic options were available, and the rate of complete cure was relatively low. Moreover, some of the old antifungal agents are associated with serious systemic side effects and should not be used for long-term therapy. The regimens were often inconvenient for the patient, resulting in low patient compliance. However, in recent years, treatment of onychomycosis has become more effective with the emergence of a new generation of antimycotics and with the use of new therapy regimens. Regimens of itraconazole given as one-week pulse therapy per month for 2 to 3 months (pulse therapy) and terbinafine given as once-daily therapy for 8 to 12 weeks (short-duration therapy), respectively, have been approved in Japan for treatment of onychomycosis.

Fluconazole, however, is not yet approved in Japan for treatment of dermatomycosis. Further, the treatment regimen for onychomycosis in particular has not been established. Despite these circumstances, fluconazole has been widely used to treat systemic fungal infections, and the regimen of fluconazole once-weekly to treat onychomycosis was reported as early as in 1991 (7). Prior to this report, there were no Japanese reports available on treatment of onychomycosis at different weekly oral dosages of fluconazole in combination with topical therapy. The aim of this study was to determine an appropriate regimen of fluconazole for safe and efficacious treatment of onychomycosis.

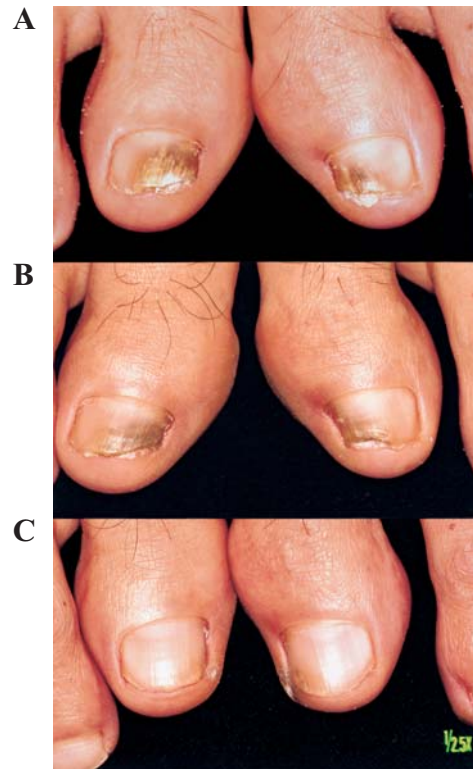

Fig. 3A. A 44-year-old male with toe-nail onychomycosis induced by *T. rubrum*.
 3B. After 6 weeks of treatment with fluconazole 100 mg/week, the turbidity and thickness of infected nail improved.
 3C. After being treated with fluconazole (57 capsules-5,700 mg in all) for 12 months, the toe-nail onychomycosis cured.

A possible limitation of our study was that patients in the 300 mg group were older than those in the other two groups and had worse overall health and more underlying systemic diseases. In addition, the mean thickness of the diseased nails in patients from the 300 mg group was greater than that of those in either of the other two groups. However, treatment efficacy in the 300 mg group was not statistically different from that in the other two groups, although the total dosage in this group was much higher (almost double) than those in the other two groups. Despite the higher total dosage, patients in the 300 mg group did not experience a higher incidence of adverse events, suggesting that higher dosage could be considered a safe treatment option for patients with severe onychomycosis, although it has been reported that the more common treatment-related adverse events in fluconazole and placebo groups are headache (6 versus 2%), abdominal pain (4 versus 3%), respiratory disorders (4 versus 3%), diarrhea (3 versus 2%), rash (3 versus 2%), and nausea (2 versus 3%), respectively (8).

Two other new generation antimycotics frequently used are terbinafine and itraconazole. The short-duration regimen of terbinafine to treat onychomycosis was introduced in 1992 when Goodfield et al. treated 112 patients with onychomycosis with 250 mg/day of terbinafine for 3 months (9). One-week monthly pulse therapy of itraconazole to treat onychomycosis was first proposed by De Doncker et al. in 1995 (10). In this open study, they proposed a regimen of itraconazole at a dose of 400 mg/d for 1 week per month, for 3-4 months in total. Over many therapeutic trials of the above regimens, the newest cumulative meta-analysis of systemic antifungal

agents for the treatment of onychomycosis revealed that the mycological cure rates of onychomycosis treated by short duration of continuous terbinafine, itraconazole pulse, and once-weekly fluconazole were $76 \pm 3\%$, $63 \pm 7\%$, and $48 \pm 5\%$, respectively (11). Our efficacy result was close to theirs for fluconazole.

Continuous administration of terbinafine has proven its efficacy mainly against dermatophyton-induced onychomycosis but does not appear necessary in view of its antifungal and pharmacokinetic qualities (12-15). The main benefit of pulse therapy with itraconazole over continuous therapy using other antifungal agents is that the systemic drug exposure in the pulse modality is much lower according to the pharmacokinetic properties of those agents (16). This aspect of treatment should reduce the risk of systemic adverse events. This modality has also improved patient compliance. On the other hand, fluconazole was more sensitive to non-dermatophyton pathogens. The once-weekly regimen was much more convenient for patients than was terbinafine short-duration therapy or itraconazole pulse therapy. Thus, compliance could be expected to be better.

In conclusion, a regimen of once-weekly fluconazole (100, 150, or 300 mg), together with daily application of 1% ketoconazole cream, was effective in treatment of onychomycosis, with an overall rate of marked improvement of 55-67% in our study population. Further, even at a double-dosage for elderly patients, once-weekly fluconazole appears safe and well tolerated for treatment of onychomycosis. Therefore, fluconazole treatment is an effective option for onychomycosis. The regimen of 150 mg once-weekly for 6 months is recommended considering efficacy, compliance, and economy. Nevertheless, the modality of 300 mg once-weekly for 3 months is still worth further investigation.

REFERENCES

1. Elewski, B. E. (1998): Once-weekly fluconazole in the treatment of onychomycosis: Introduction. *J. Am. Acad. Dermatol.*, 38, 73-76.
2. Elewski, B. E. and Charif, M. A. (1997): Prevalence of onychomycosis in patients attending a dermatology clinic in northeastern Ohio for other conditions. *Arch. Dermatol.*, 133, 1172-1173.
3. Millikan, L. E., Powell, D. W. and Drake, L. A. (1999): Quality of life for patients with onychomycosis. *Int. J. Dermatol.*, 38 (Suppl. 2), 13-16.
4. Summerbell, R. C., Kane, J. and Kraiden, S. (1989): Onychomycosis, tinea pedis and tinea manuum caused by non-dermatophytic filamentous fungi. *Mycosis*, 32, 609-619.
5. Zaias, N., Glick, B. and Rebell, G. (1996): Diagnosing and treating onychomycosis. *J. Fam. Pract.*, 42, 513-518.
6. Rich, P., Scher, R. K., Braneman, D., Savin, R. C., Feingold, D. S. and Konnikov, N. (1998): Pharmacokinetics of three doses of once-weekly fluconazole (150, 300, and 450 mg) in distal subungual onychomycosis of the toenail. *J. Am. Acad. Dermatol.*, 38, 103-109.
7. Monteiro-Gei, F., Melendez, M. and Siles, L. (1991): Fluconazole in the treatment of onychomycosis. p. 142. Program and Abstract. The XI Congress of the International Society for Human and Animal Mycology, Montreal, Quebec: ISHAM.
8. Gupta, A. K. and Shear, N. H. (1999): Safety review of the oral antifungal agents used to treat superficial mycosis. *Int. J. Dermatol.*, 38 (Suppl.), 40-52.
9. Goodfield, M. J., Andrew, L. and Evans, E. G. (1992): Short term treatment of dermatophyte onychomycosis with terbinafine. *Br. Med. J.*, 304, 1151-1154.
10. De Doncker, P., Van Lint, J., Dockx, P. and Roseeuw, D. (1995): Pulse therapy with one-week itraconazole monthly for three or four months in the treatment of onychomycosis. *Cutis*, 56, 180-183.
11. Gupta, A. K., Ryder, J. E. and Johnson, A. M. (2004): Cumulative meta-analysis of systemic antifungal agents for the treatment of onychomycosis. *Br. J. Dermatol.*, 150, 537-544.
12. Finlay, A. Y. (1992): Pharmacokinetics of terbinafine in the nail. *Br. J. Dermatol.*, 126, 28-32.
13. Zaias, N. (1992): Clinical manifestations of onychomycosis. *Clin. Exp. Dermatol.*, 17 (Suppl.), 6-7.
14. Midgley, G., Moore, M. K., Cook, J. C. and Phan, Q. G. (1994): Mycology of nail disorders. *J. Am. Acad. Dermatol.*, 31, 68-74.
15. Hay, R. J. (1993): Onychomycosis, agents of choice. *Dermatol. Clin.*, 11, 161-169.
16. De Doncker, P. (1999): Pharmacokinetics of orally administered antifungals in onychomycosis. *Int. J. Dermatol.*, 38 (Suppl.), 20-27.